

# Functional Magnetic Resonance Imaging (fMRI)

*and a few other brain imaging techniques*

## History, Development, and Applications

Peter A. Bandettini, Ph.D.

[bandettini@nih.gov](mailto:bandettini@nih.gov)

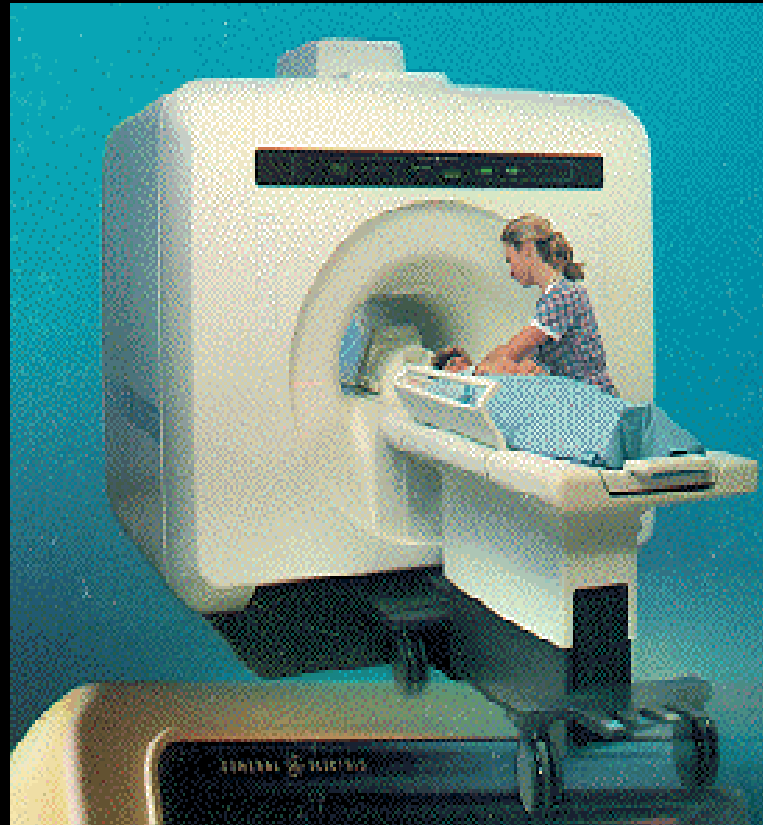

# Two Types of Neuroimaging

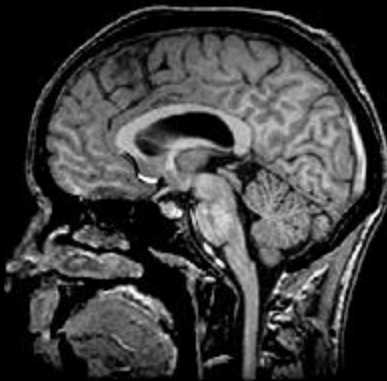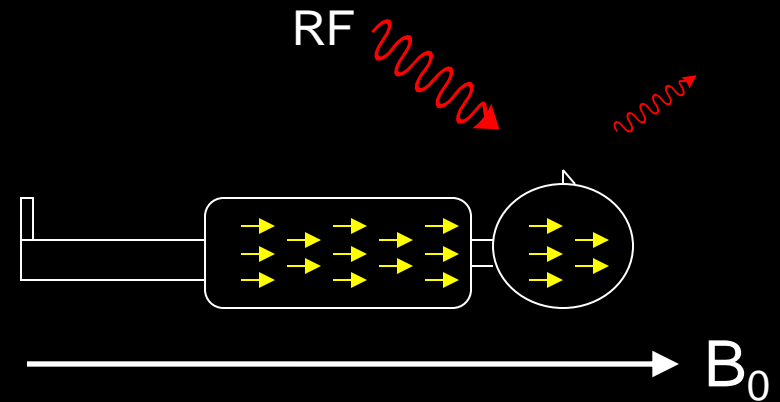
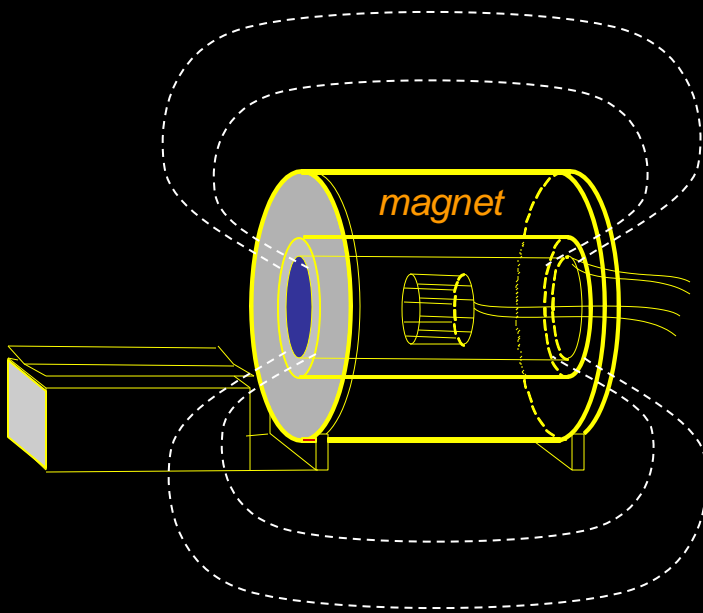
- Structural/Anatomical Imaging
- Functional Imaging

- **Structural/Anatomical Imaging**
  - X-ray
  - Computerized Tomography (CT)
  - Magnetic Resonance Imaging (MRI)
    - Angiography
    - Venography
    - Perfusion
    - Diffusion Tensor Imaging

# Magnetic Resonance Imaging



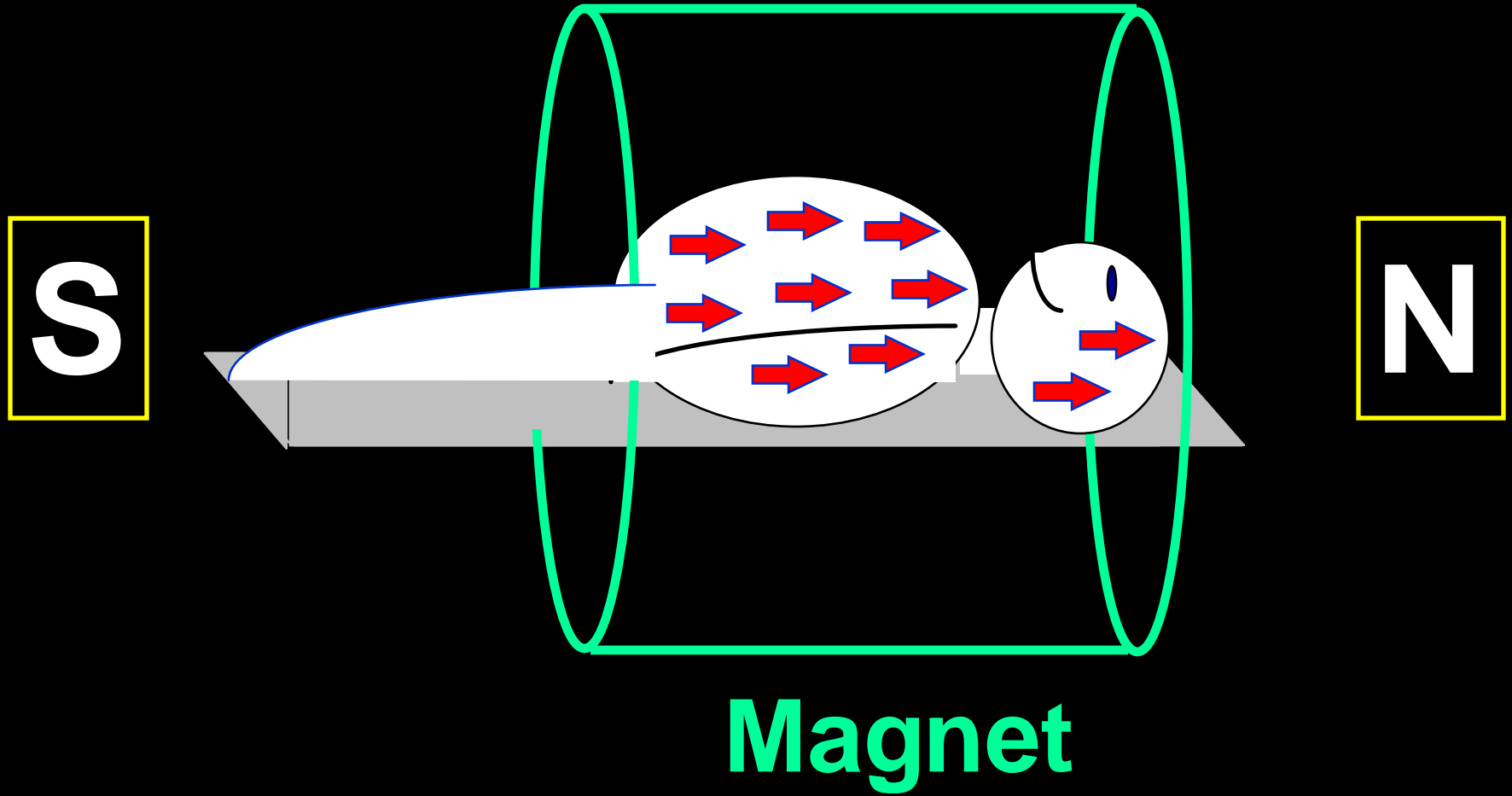
# Magnetic Resonance Imaging (MRI)



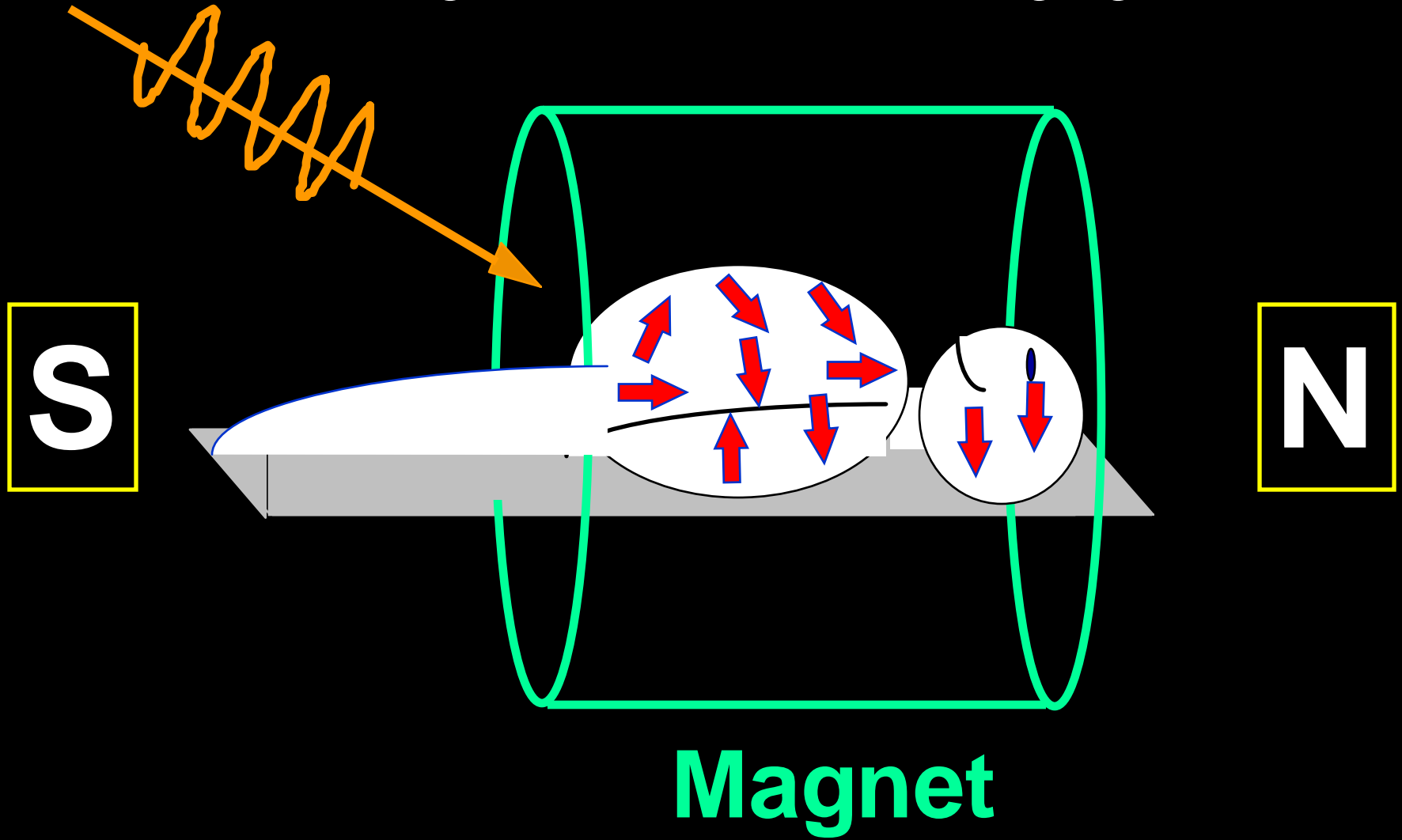
Sensitive to:

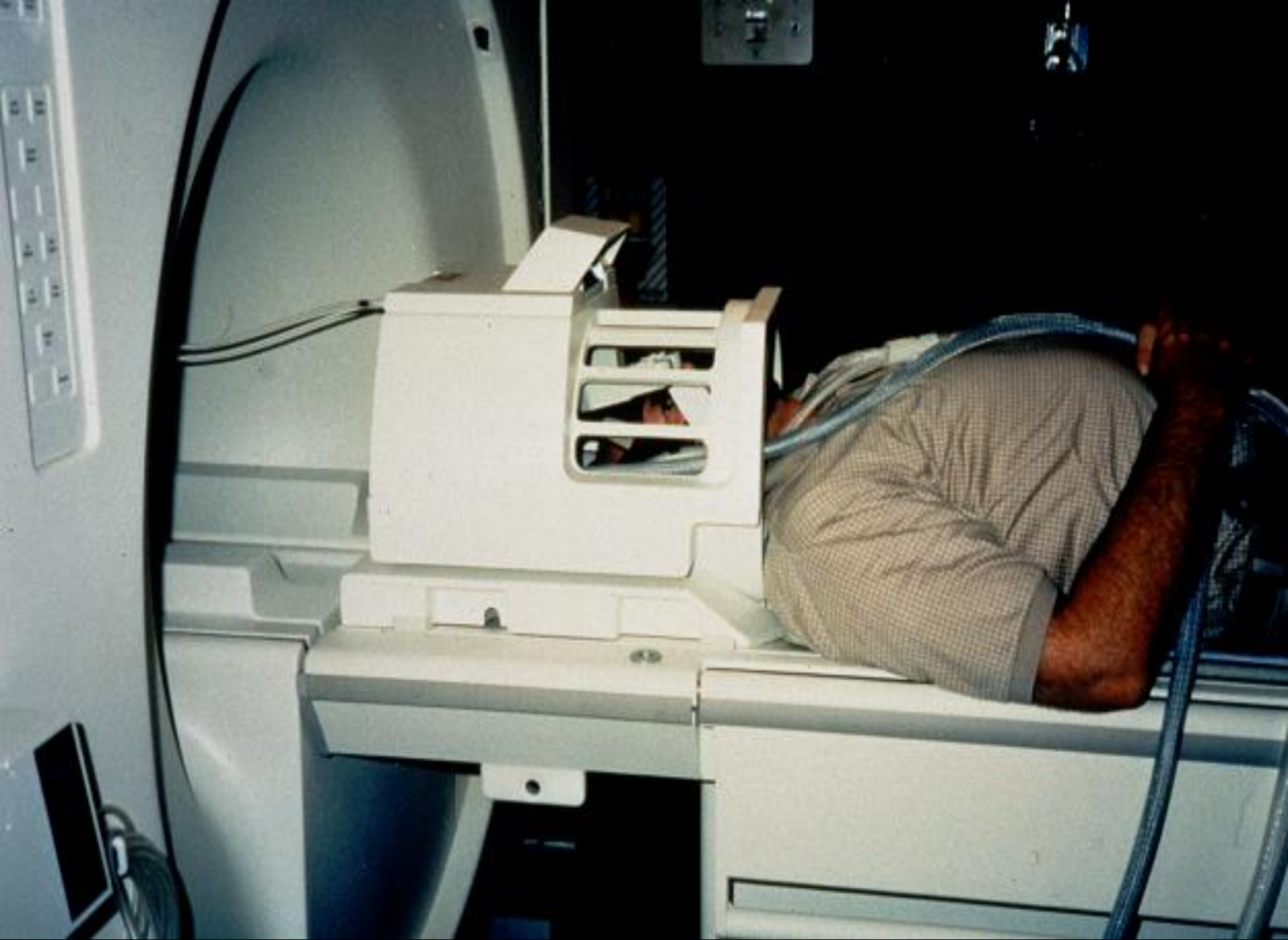- # of protons ( $H_2O$ )
- Magnetic environment
  - Tissue structure

# Magnetic Resonance Imaging



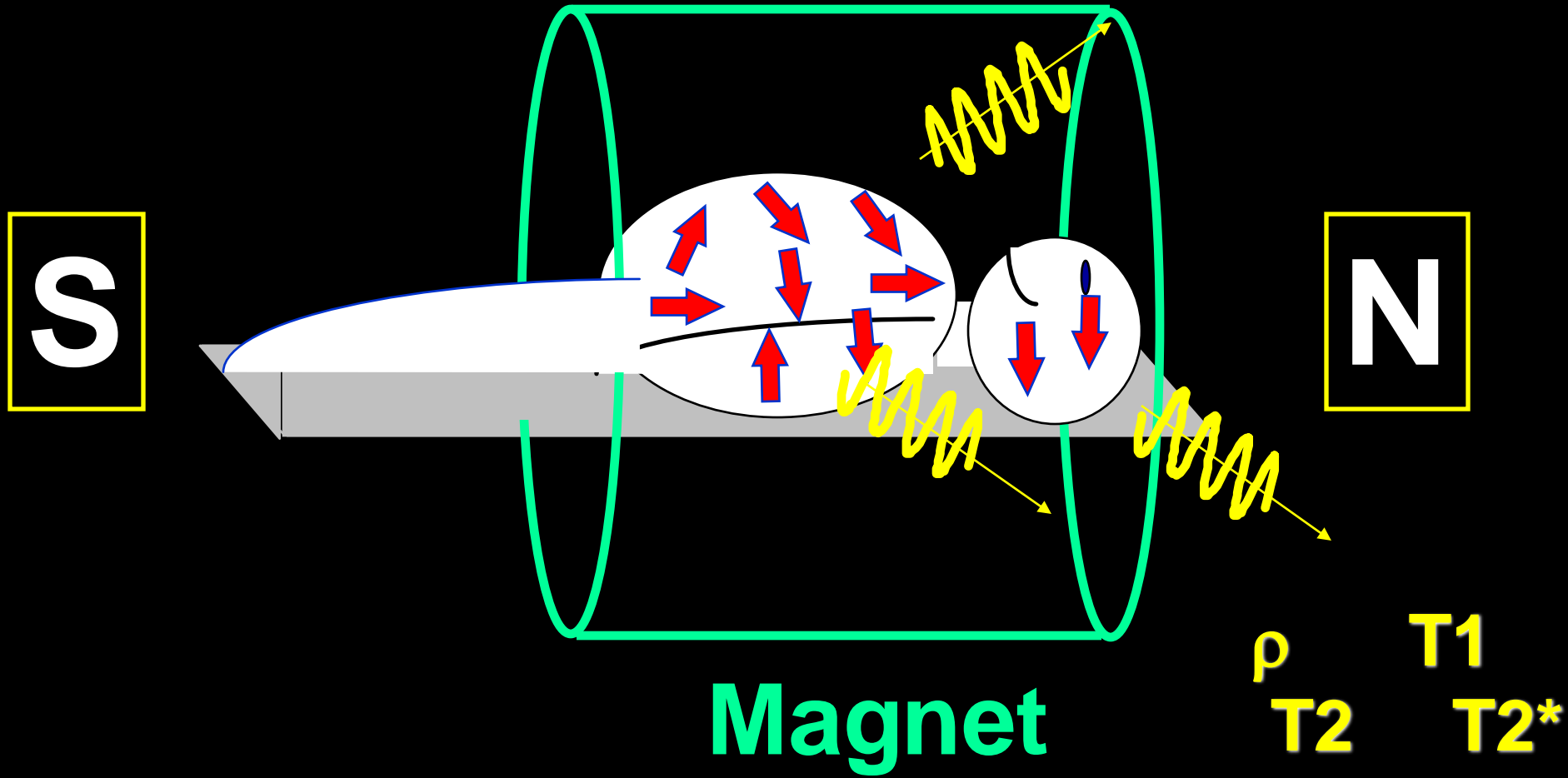
# Magnetic Resonance Imaging





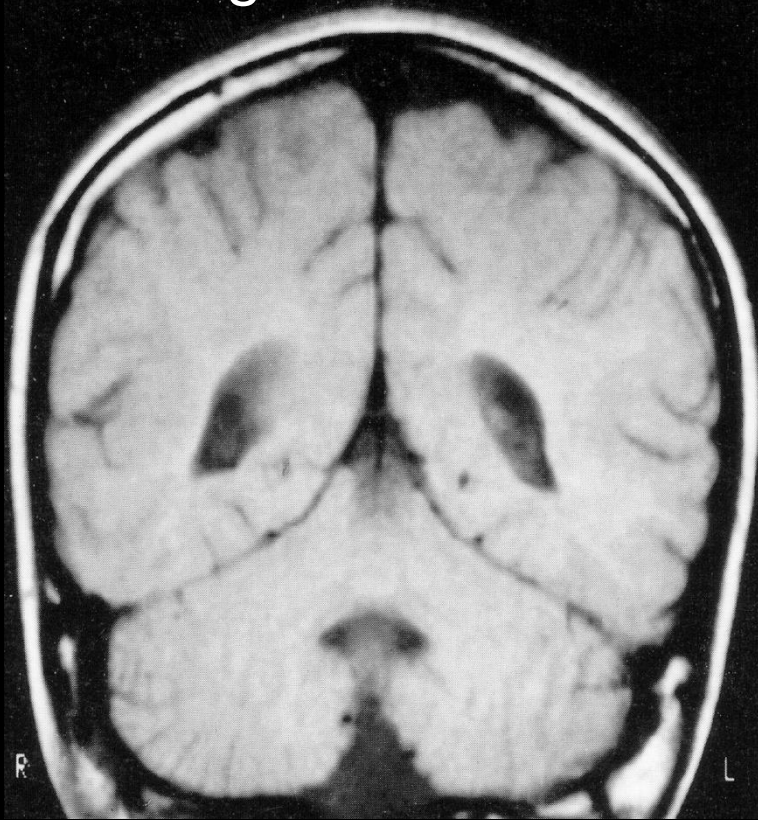


# Magnetic Resonance Imaging

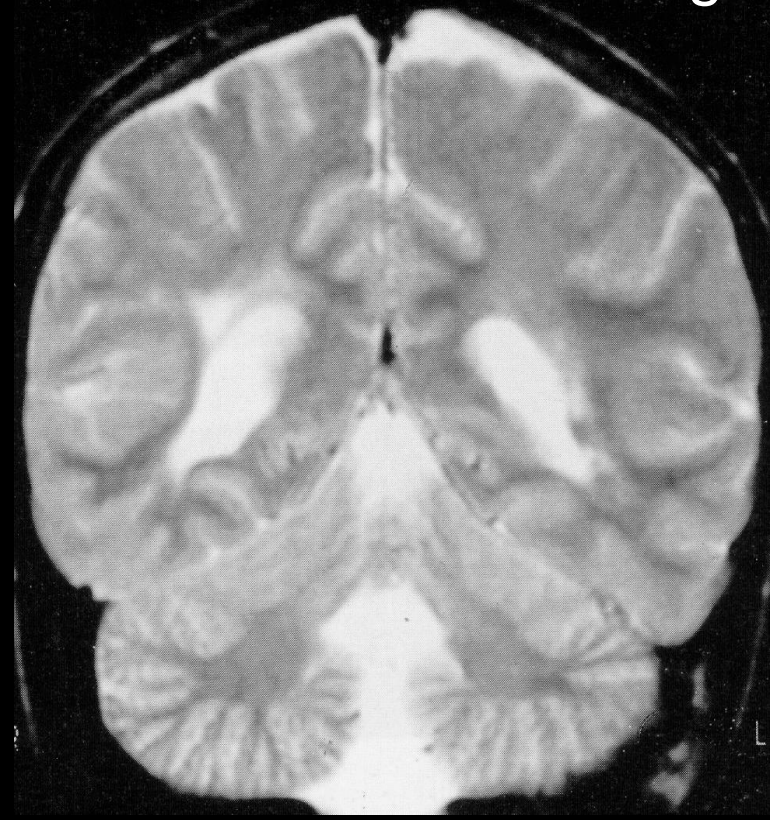


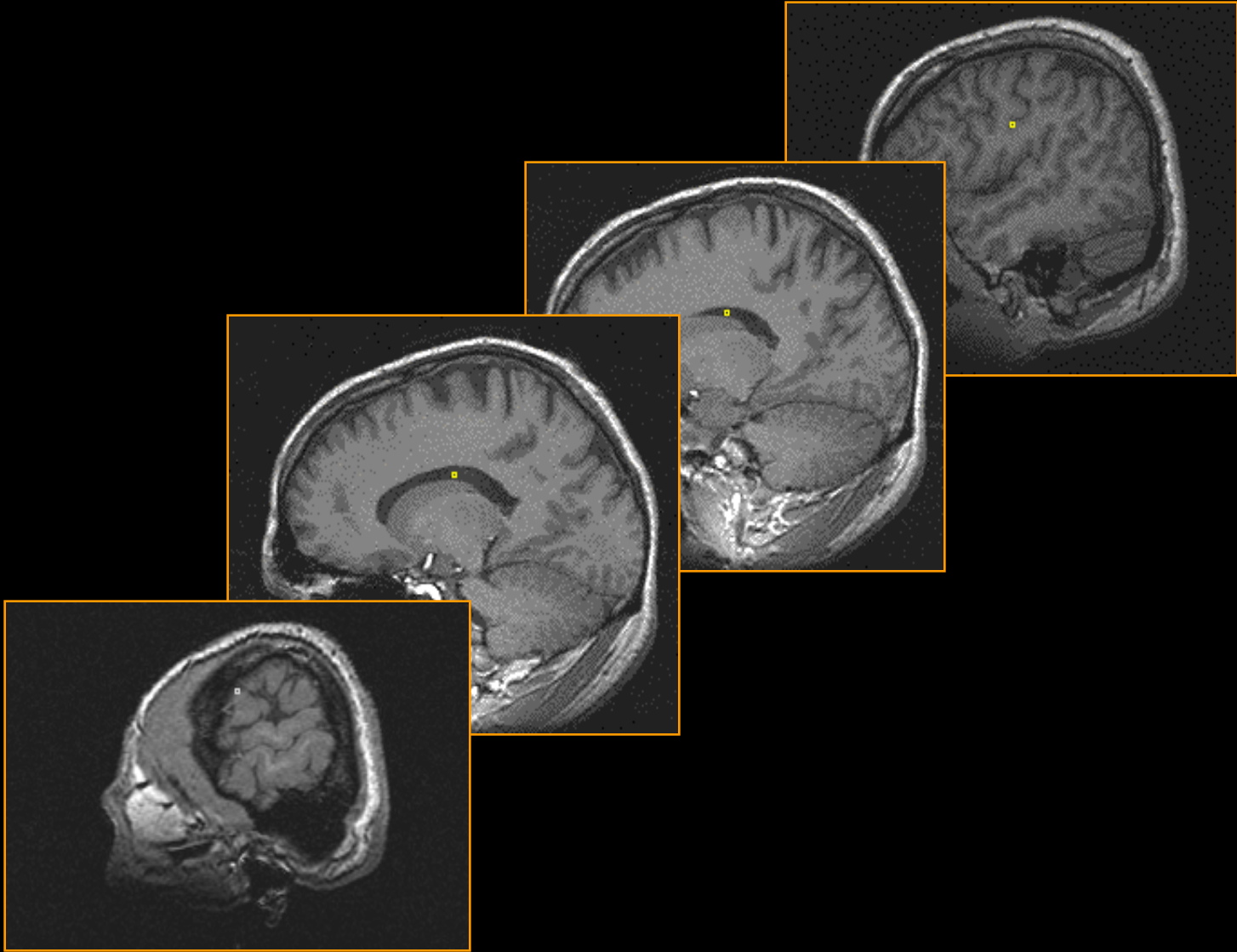
# MRI Images with Different Contrast Weighting

T1 Weighted



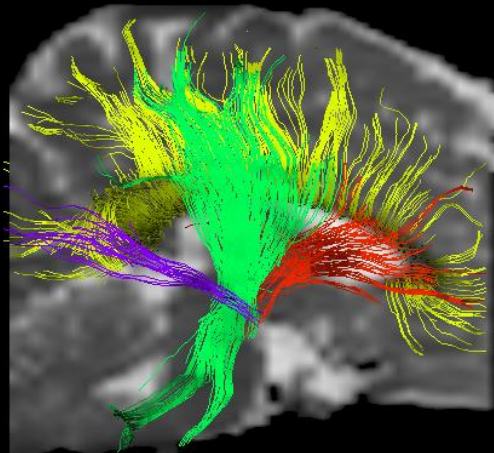
T2 Weighted



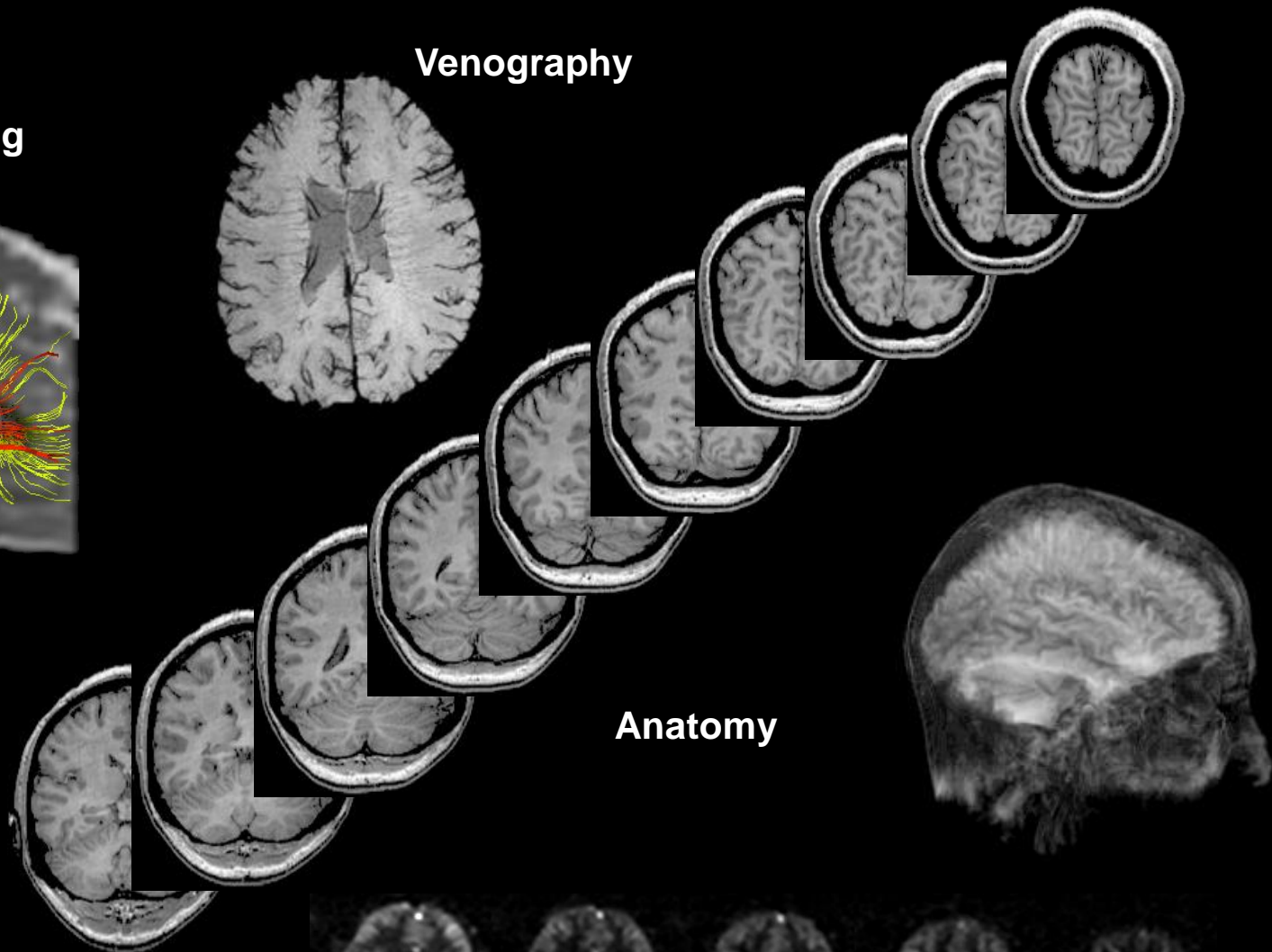
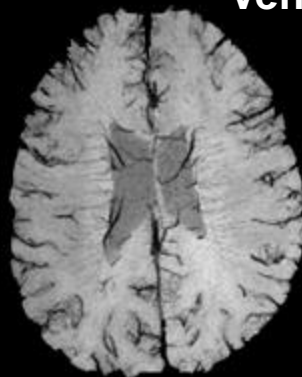




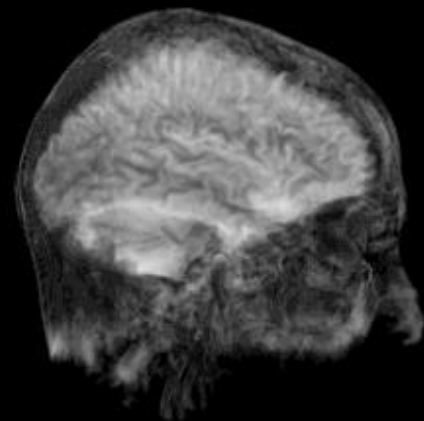
**Fiber Track Imaging**



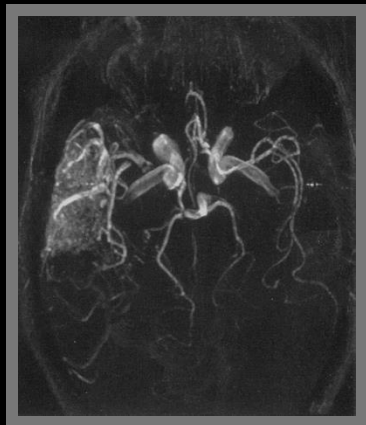**Venography**



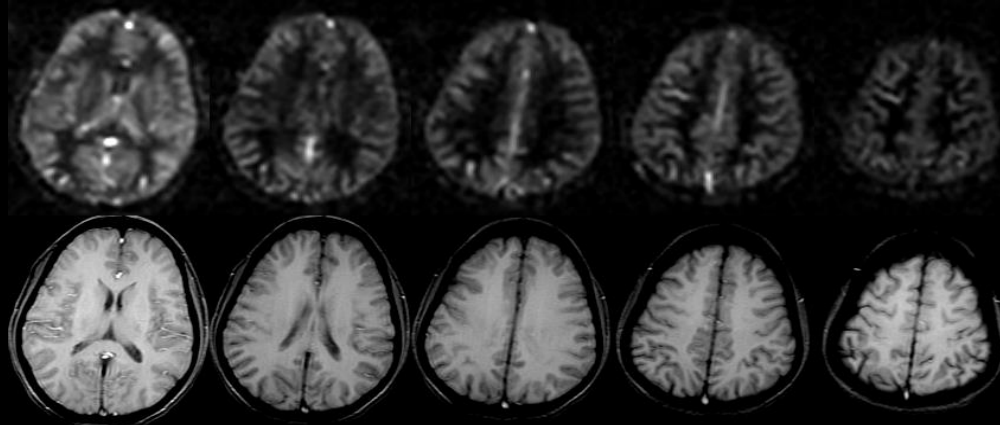
**Anatomy**



**Angiography**



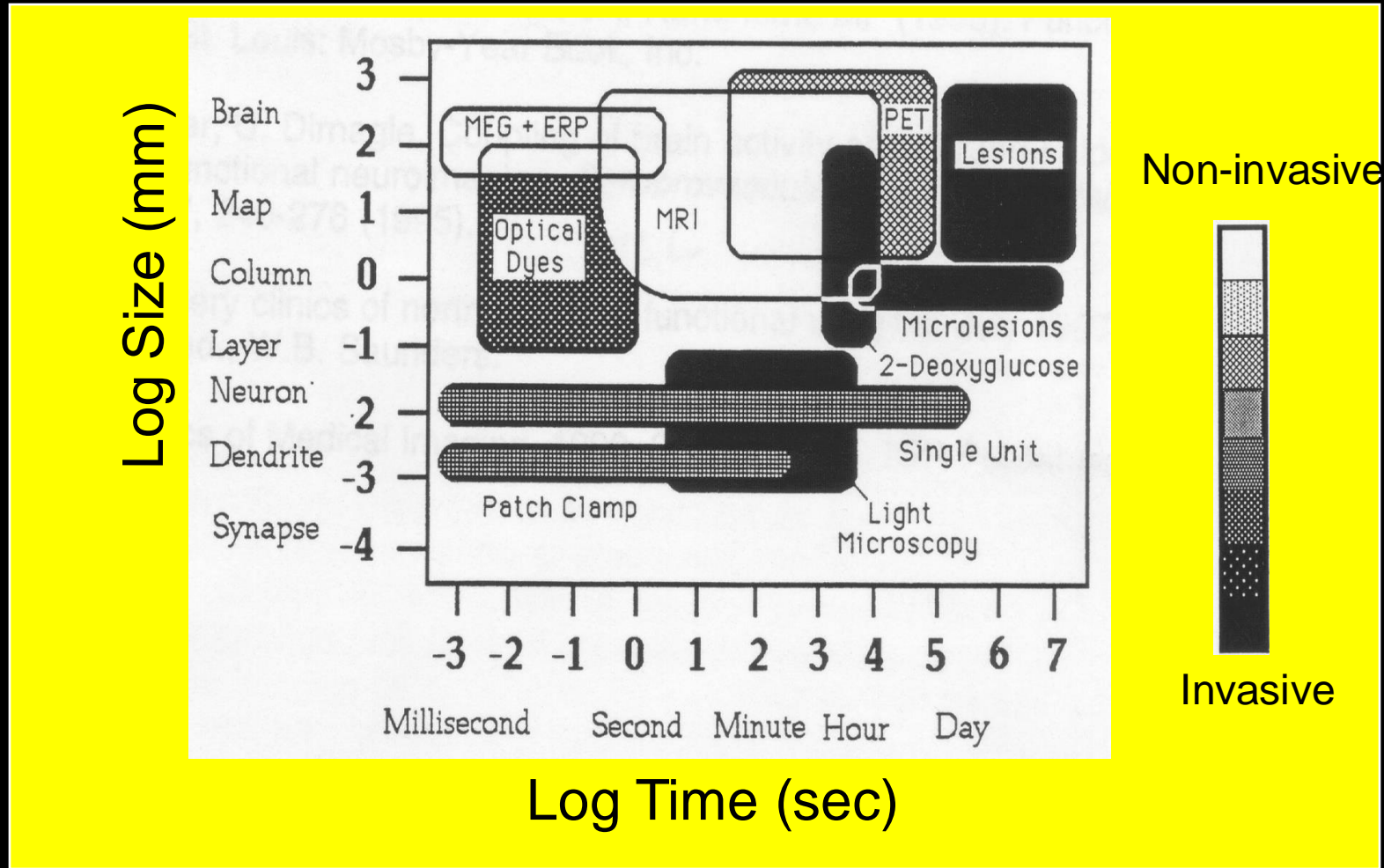
**Perfusion**



# •Functional Imaging


- Xenon Computerized Tomography (Xe CT)
- Positron Emission Tomography (PET)
- Single Photon Computed Tomography (SPECT)
- Functional MRI (fMRI)
- Electroencephalography (EEG)
- Magnetoencephalography (MEG)
- Transcranial Magnetic Stimulation (TMS)

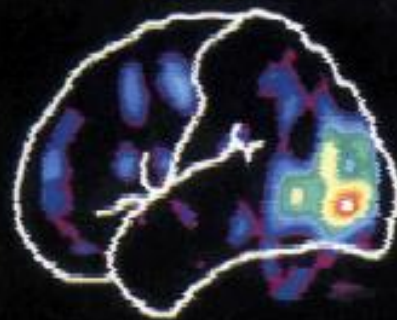
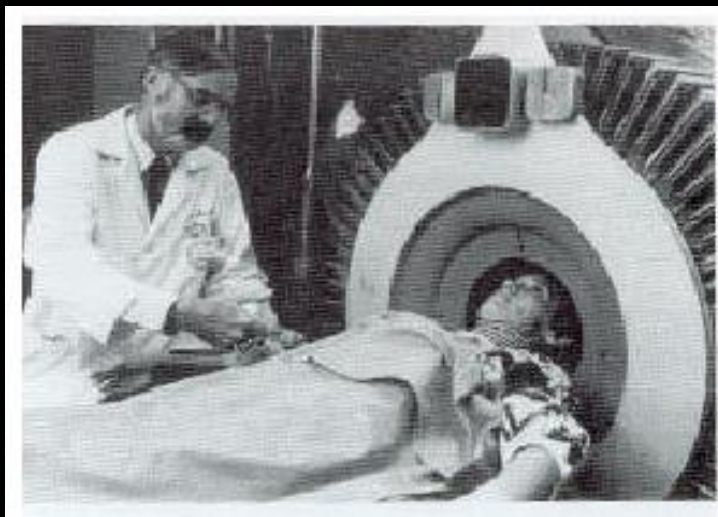# Functional Neuroimaging Techniques



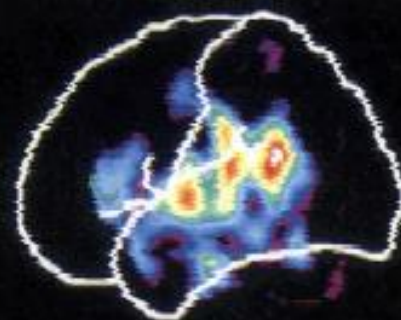
# Positron Emission Tomography (PET)

- Positron emission tomography (PET) is a technique for studying functional processes *in vivo* by measuring the concentrations of positron-emitting radioisotopes within the subject.
- PET is primarily used to study biochemical and physiological processes within living organs.

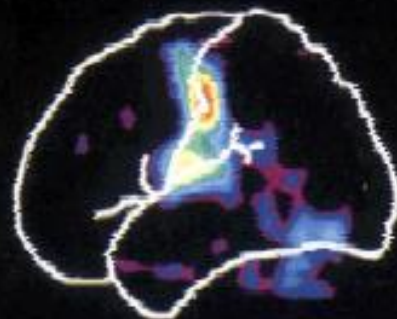




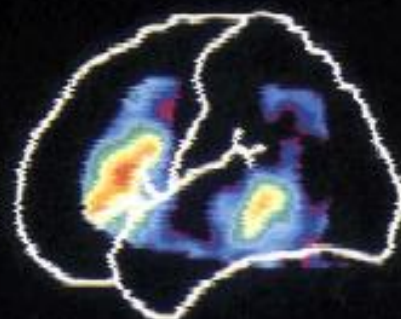
*Passively viewing words*



*Listening to words*



*Speaking words*

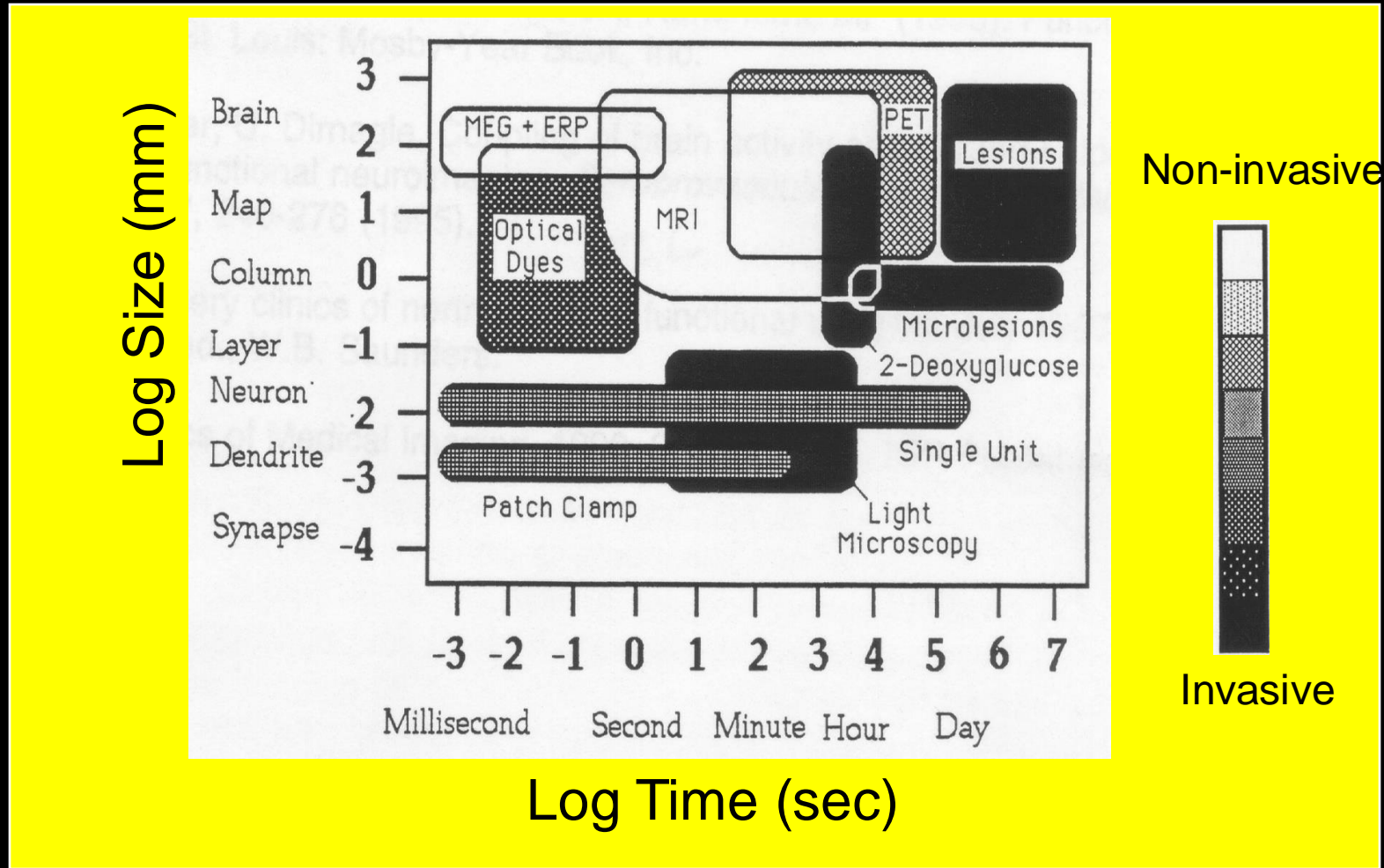


*Generating verbs*

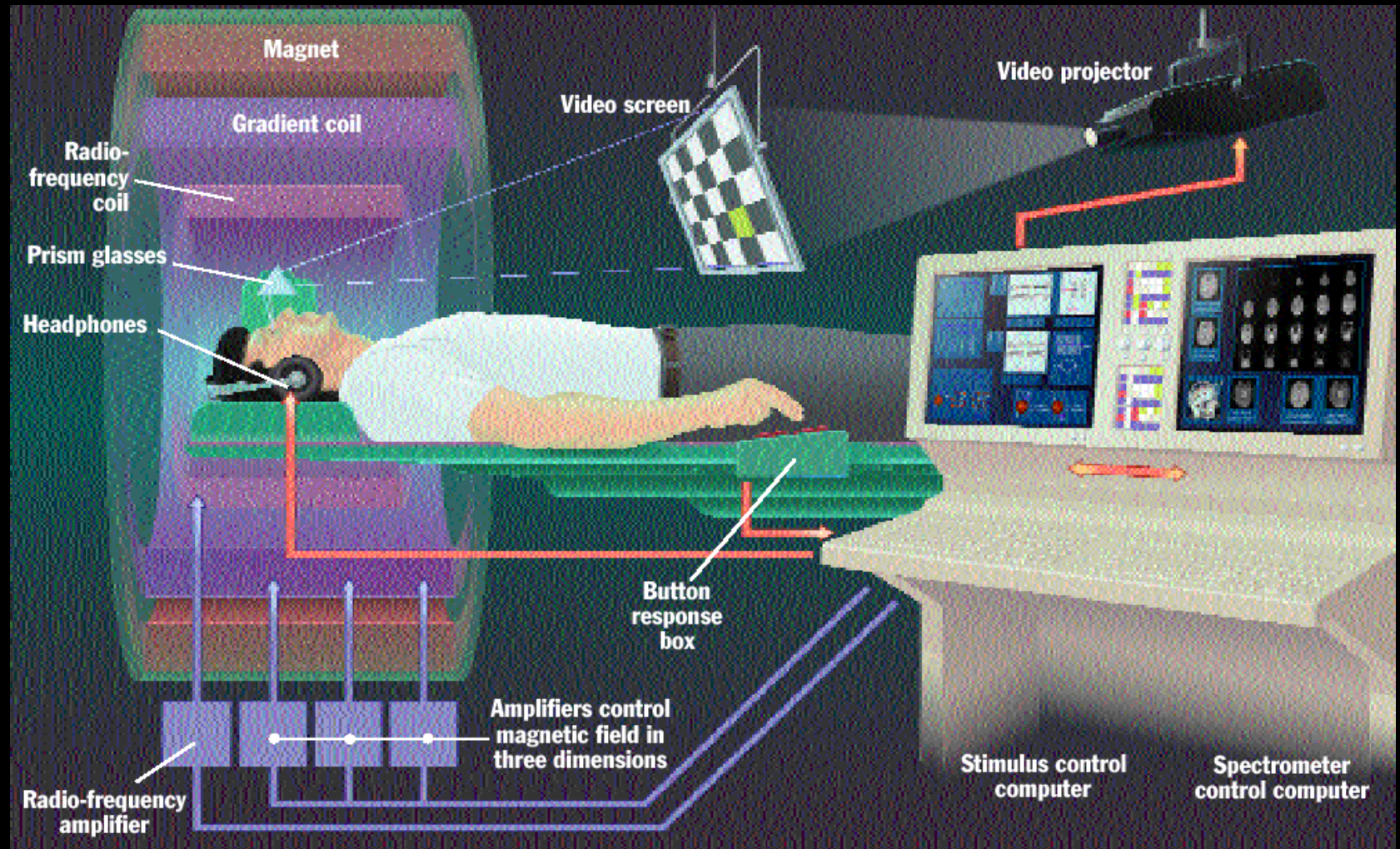


# Functional Magnetic Resonance Imaging

# Functional Neuroimaging Techniques



# fMRI Setup



Courtesy, Robert Cox,  
Scientific and Statistical  
Computing Core Facility,  
NIMH





# Scanners:


- “3T-1” GE 3T (June 2000)
- “3T-2” GE 3T (Nov 2002)
- “FMRIF 1.5T” GE 1.5T (Sept 2004)
- Currently being Cited GE 3T (Aug 2003)



1.5T



3T-1

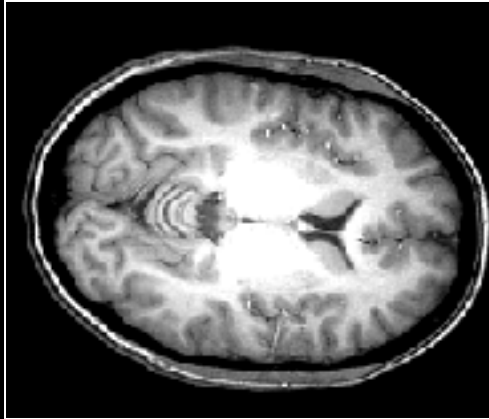


3T-2

# MRI vs. fMRI

**MRI**

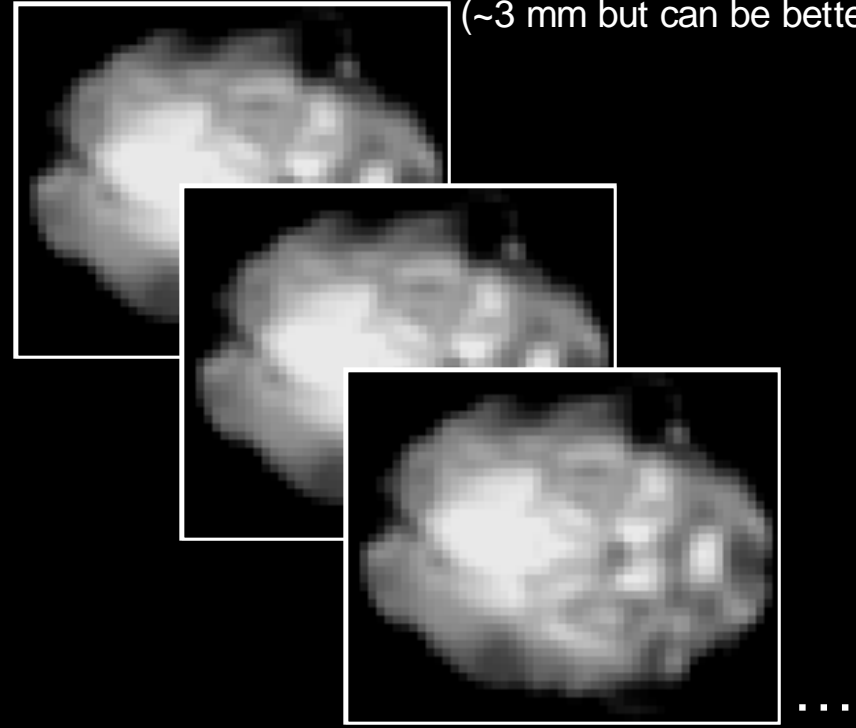
high resolution  
(1 mm)




one image

**fMRI**

low resolution  
(~3 mm but can be better)



many images  
(e.g., every 2 sec for 5 mins)



August, 1991



**1991-1992**

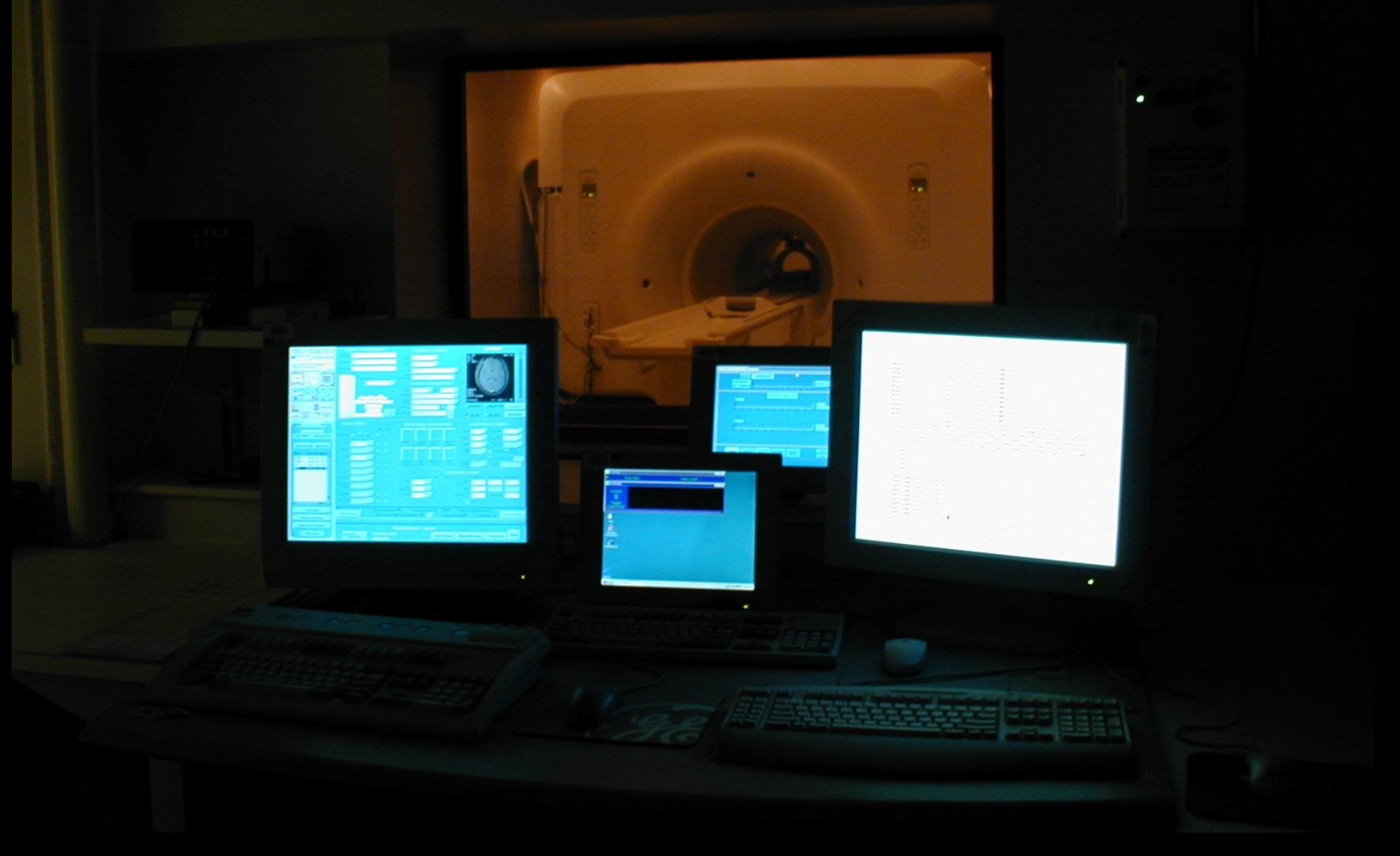

**1992-1999**



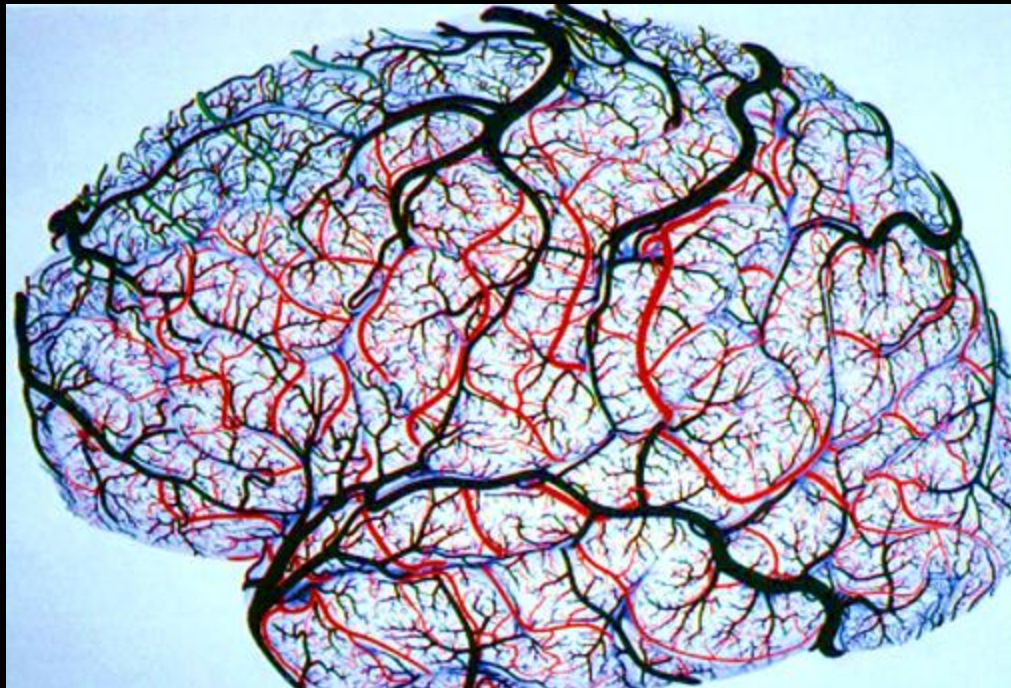

# General Electric 3 Tesla Scanner

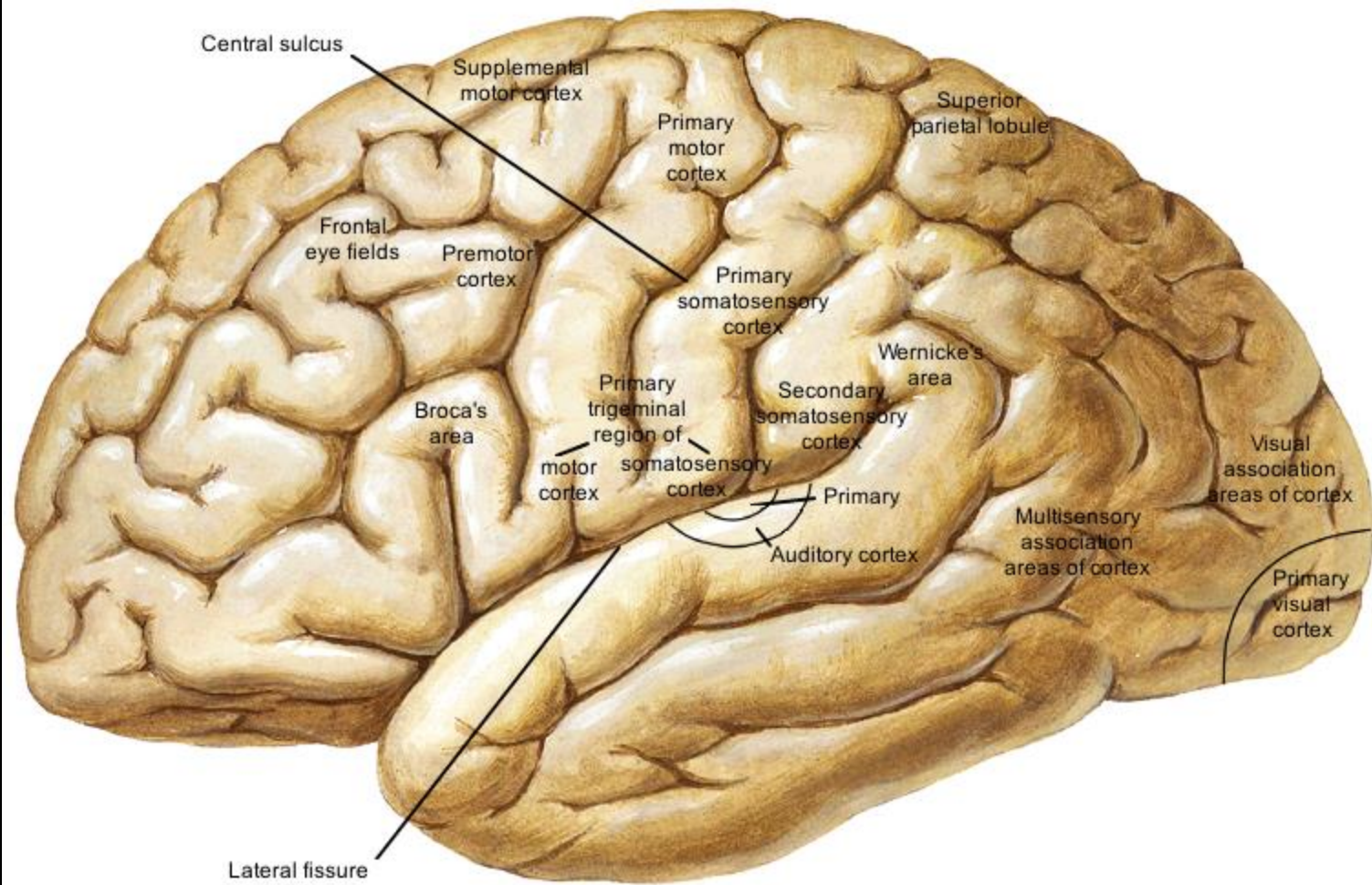


# Contrast in Functional MRI

- Blood Volume
- Blood Oxygenation Changes
  - Blood Oxygenation Level Dependent Contrast (BOLD)
- Blood Perfusion



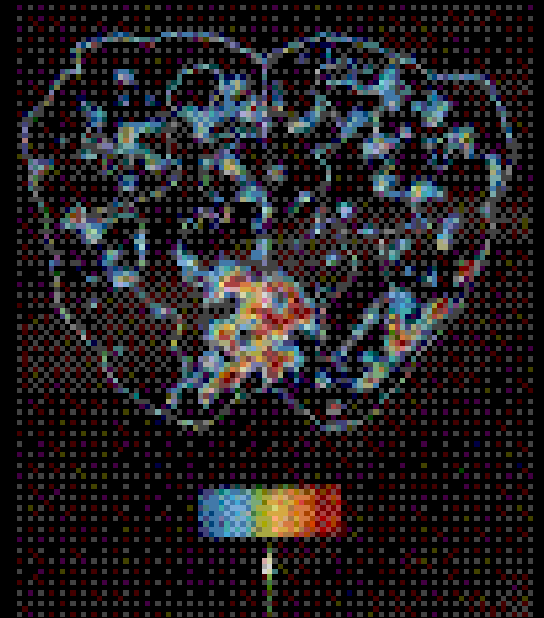




# Blood Volume Changes with Brain Activation

**Resting**

**Active**

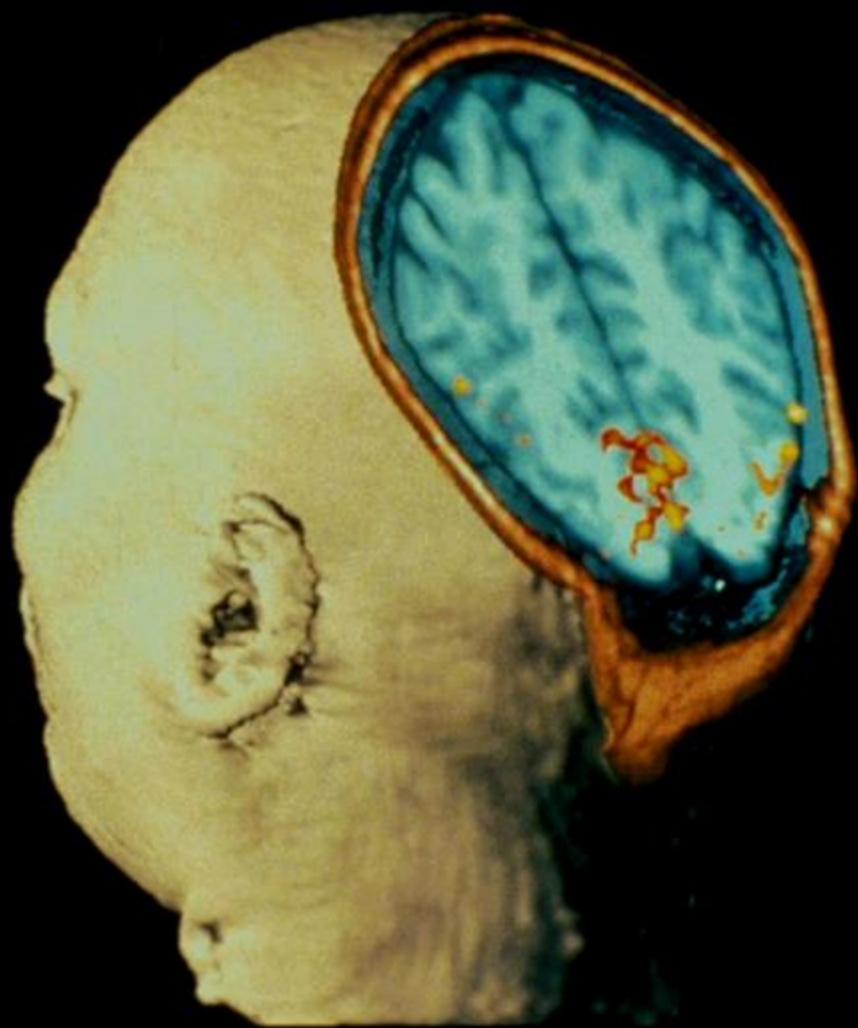


# Photic Stimulation

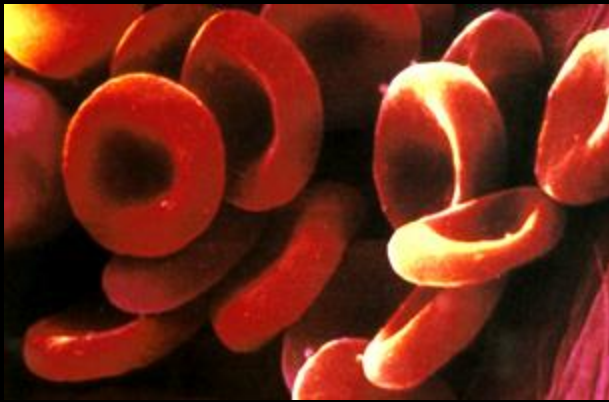MRI Image showing  
activation of the  
Visual Cortex

From Belliveau, et al.  
Science Nov 1991

MSC - perfusion




*Oxygenated and deoxygenated red blood cells have different magnetic properties*

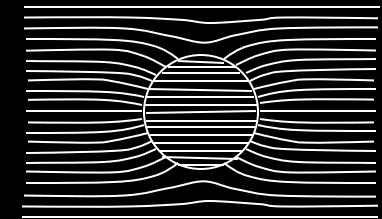


red blood cells

oxygenated



deoxygenated



L. Pauling, C. D. Coryell, *Proc. Natl. Acad. Sci. USA* 22, 210-216, **1936**.

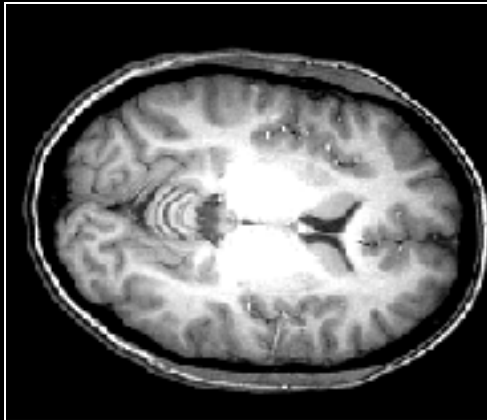
K.R. Thulborn, J. C. Waterton, et al., *Biochim. Biophys. Acta.* 714: 265-270, **1982**.

S. Ogawa, T. M. Lee, A. R. Kay, D. W. Tank, *Proc. Natl. Acad. Sci. USA* 87, 9868-9872, **1990**.

# MRI vs. fMRI

high resolution  
(1 mm)

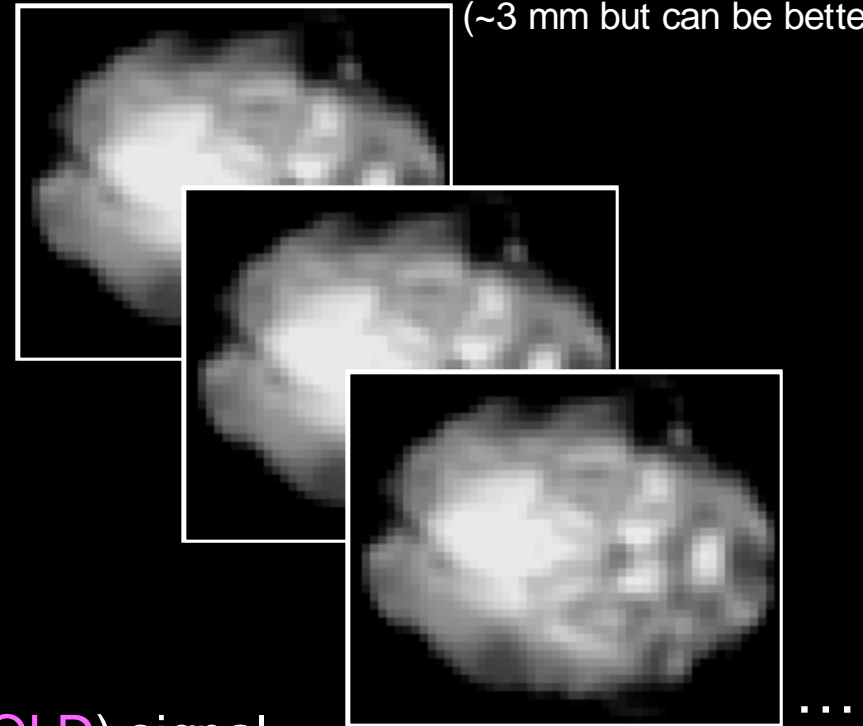
**MRI**



one image

**fMRI**

low resolution  
(~3 mm but can be better)



many images  
(e.g., every 2 sec for 5 mins)

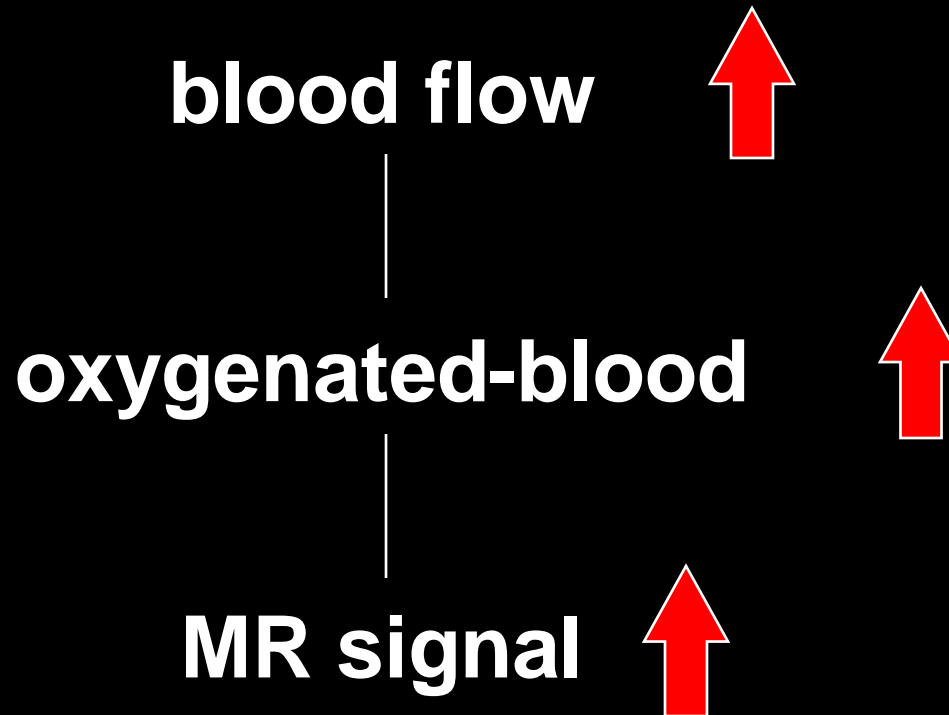
**fMRI**

Blood Oxygenation Level Dependent (BOLD) signal  
indirect measure of neural activity

↑ neural activity → ↑ blood oxygen → ↑ fMRI signal

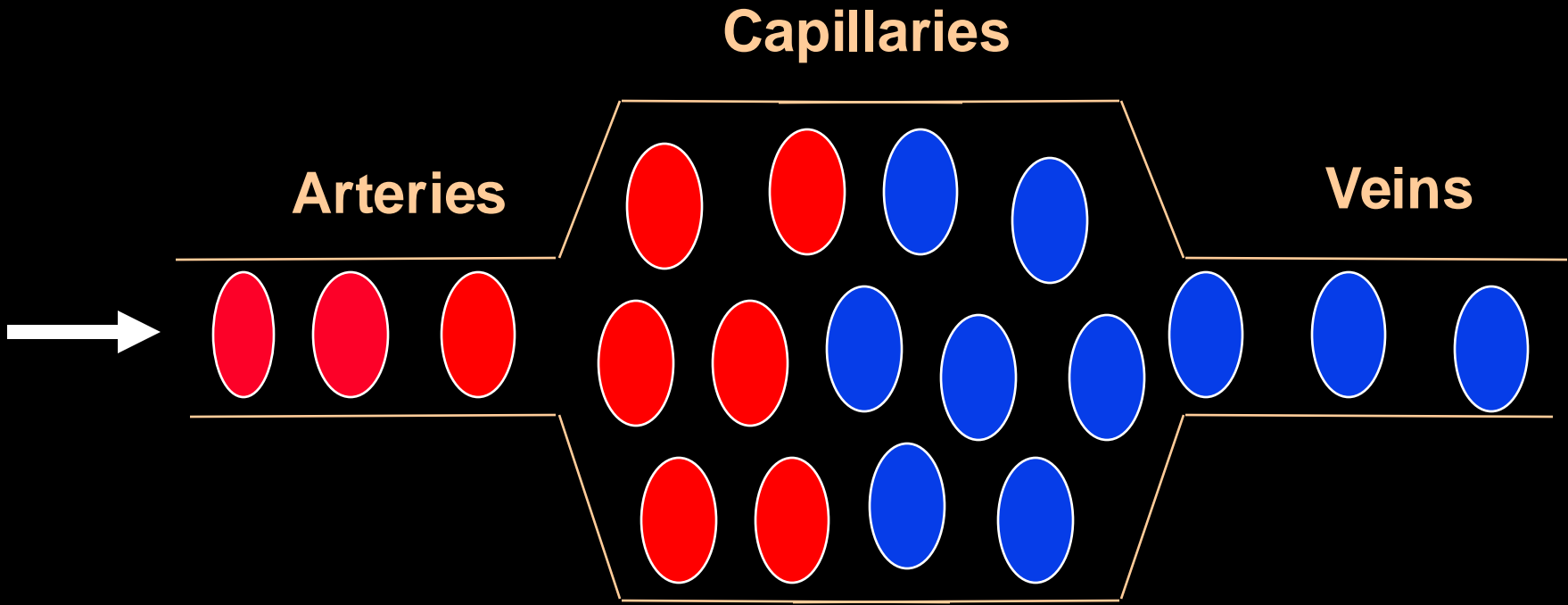
# BOLD

(blood oxygenation level dependence)



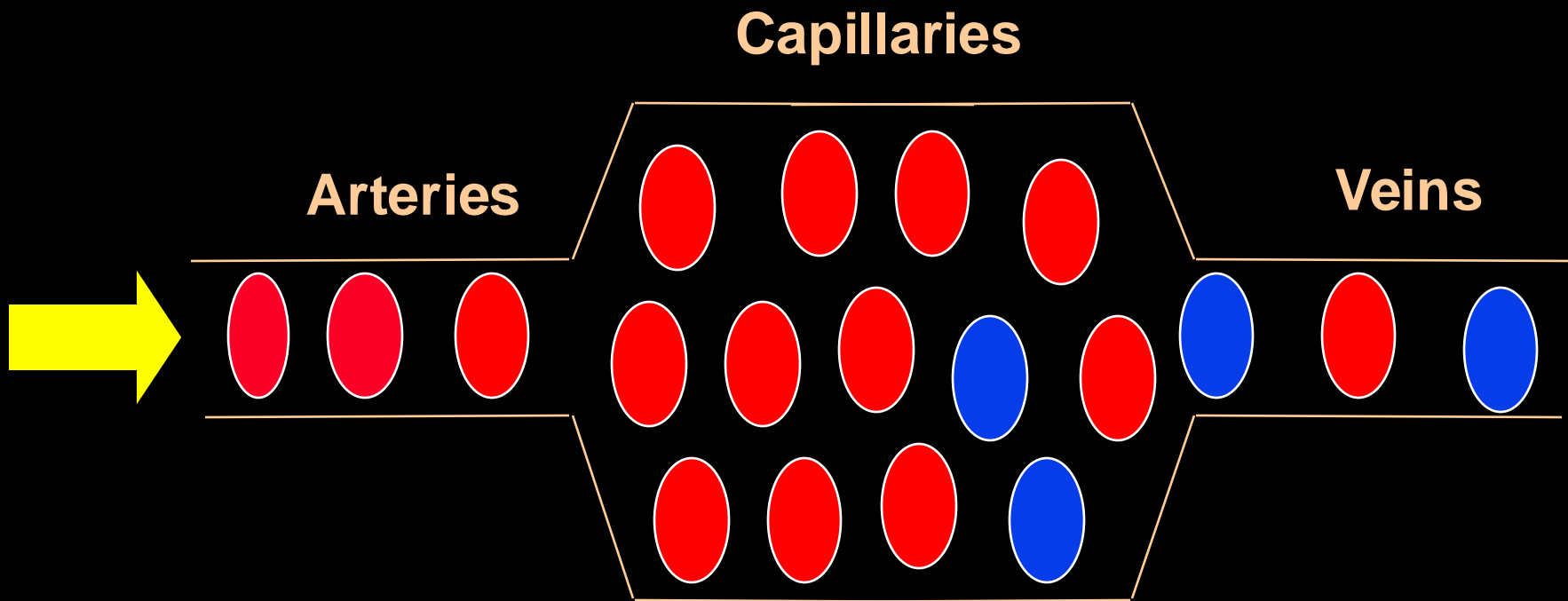


# BOLD: Resting flow



**SIGNAL**

# **BOLD: Activated flow**



**SIGNAL**



# Alternating Left and Right Finger Tapping



# Real Time Brain Activation Imaging

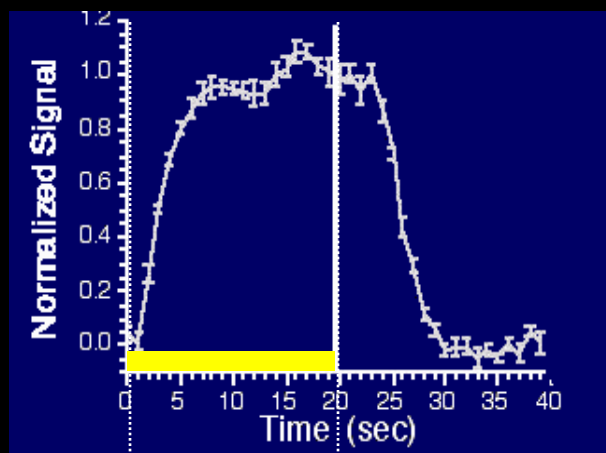


•K. K. Kwong, et al, (1992) “Dynamic magnetic resonance imaging of human brain activity during primary sensory stimulation.” Proc. Natl. Acad. Sci. USA. 89, 5675-5679.

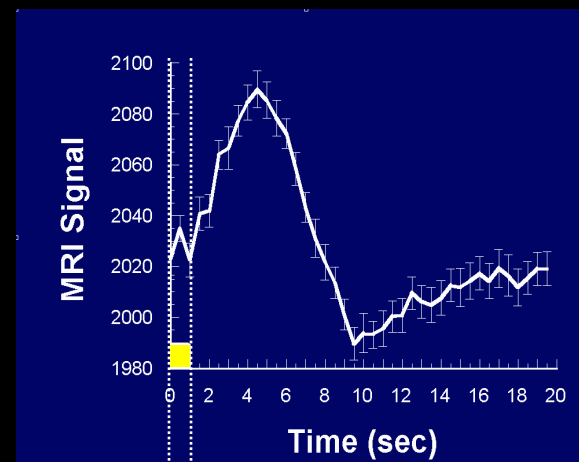
•S. Ogawa, et al., (1992) “Intrinsic signal changes accompanying sensory stimulation: functional brain mapping with magnetic resonance imaging. Proc. Natl. Acad. Sci. USA.” 89, 5951-5955.

•P. A. Bandettini, et al., (1992) “Time course EPI of human brain function during task activation.” Magn. Reson. Med 25, 390-397.

•Blamire, A. M., et al. (1992). “Dynamic mapping of the human visual cortex by high-speed magnetic resonance imaging.” Proc. Natl. Acad. Sci. USA 89: 11069-11073.



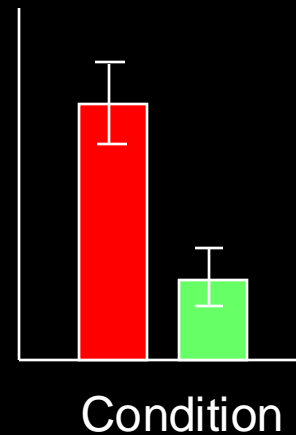
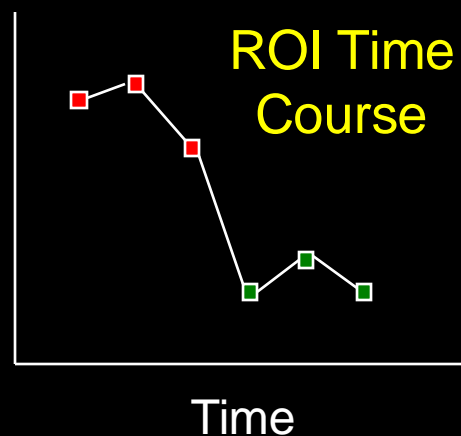
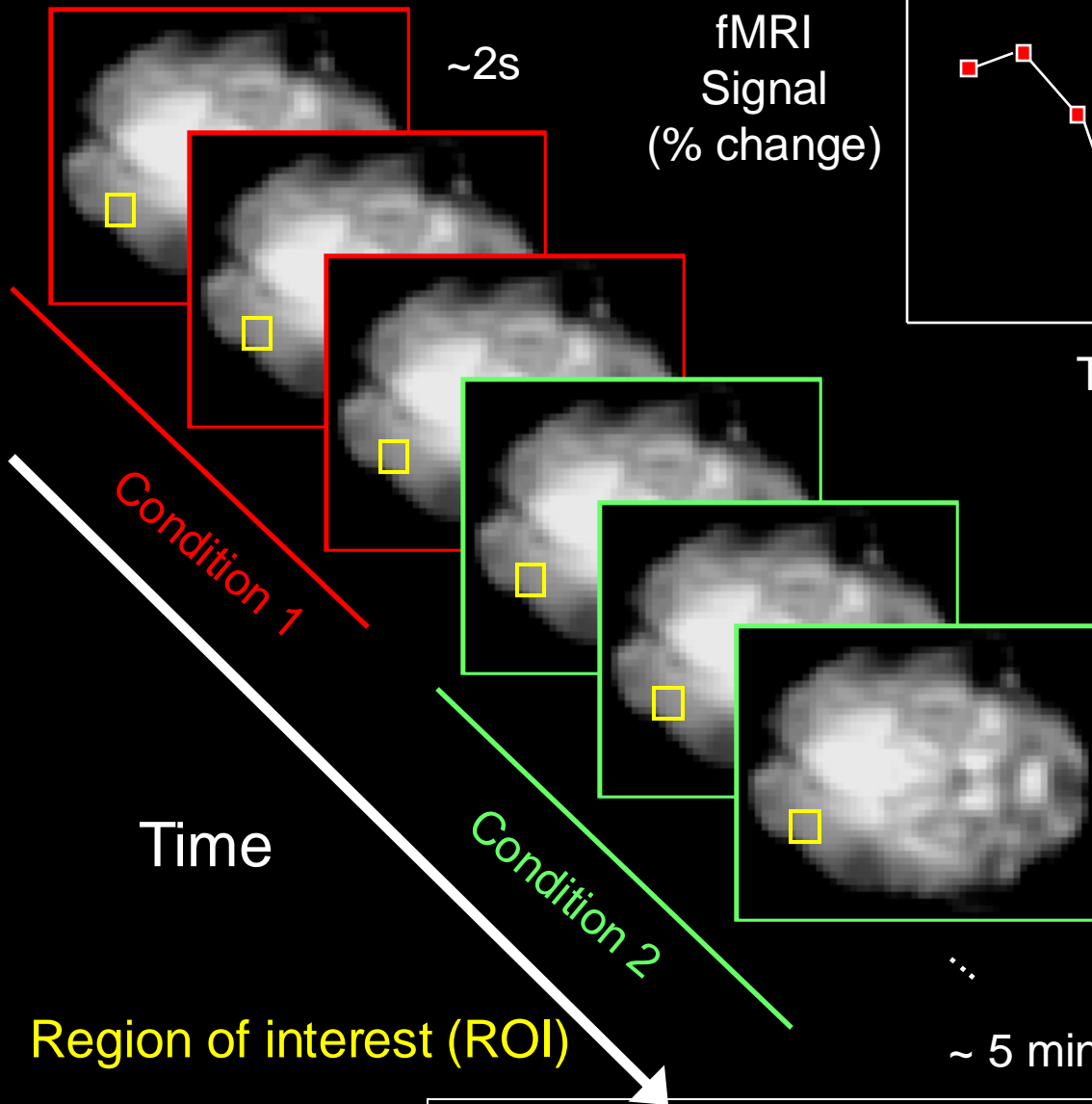
*task*



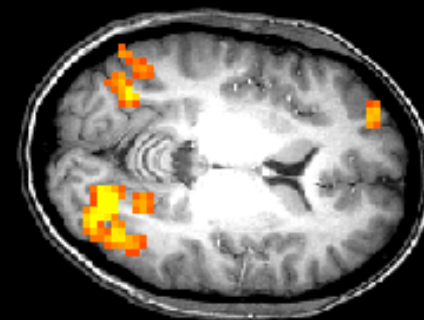
*task*

# Activation Statistics

Functional images

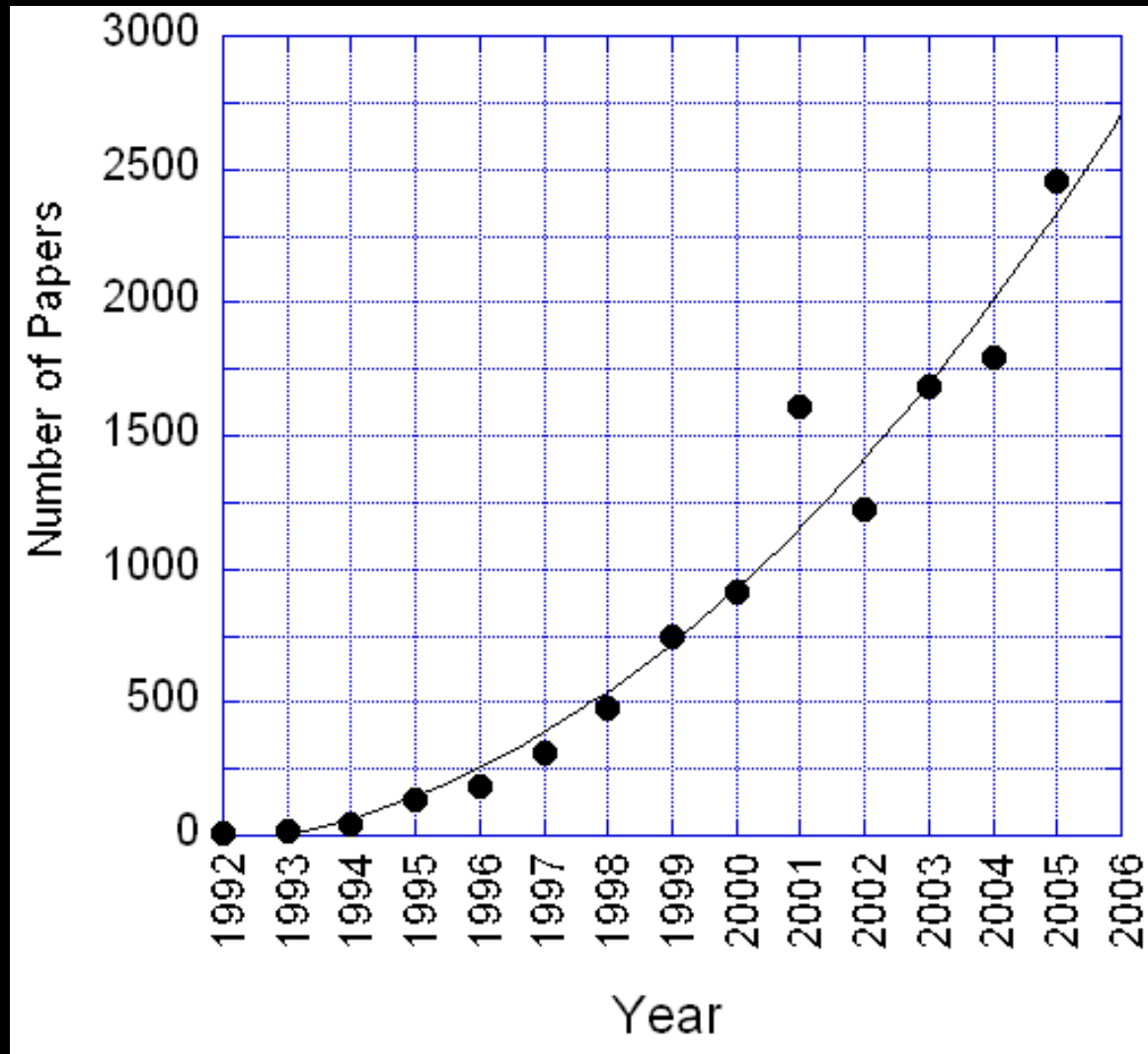


Statistical Map  
superimposed on  
anatomical MRI image



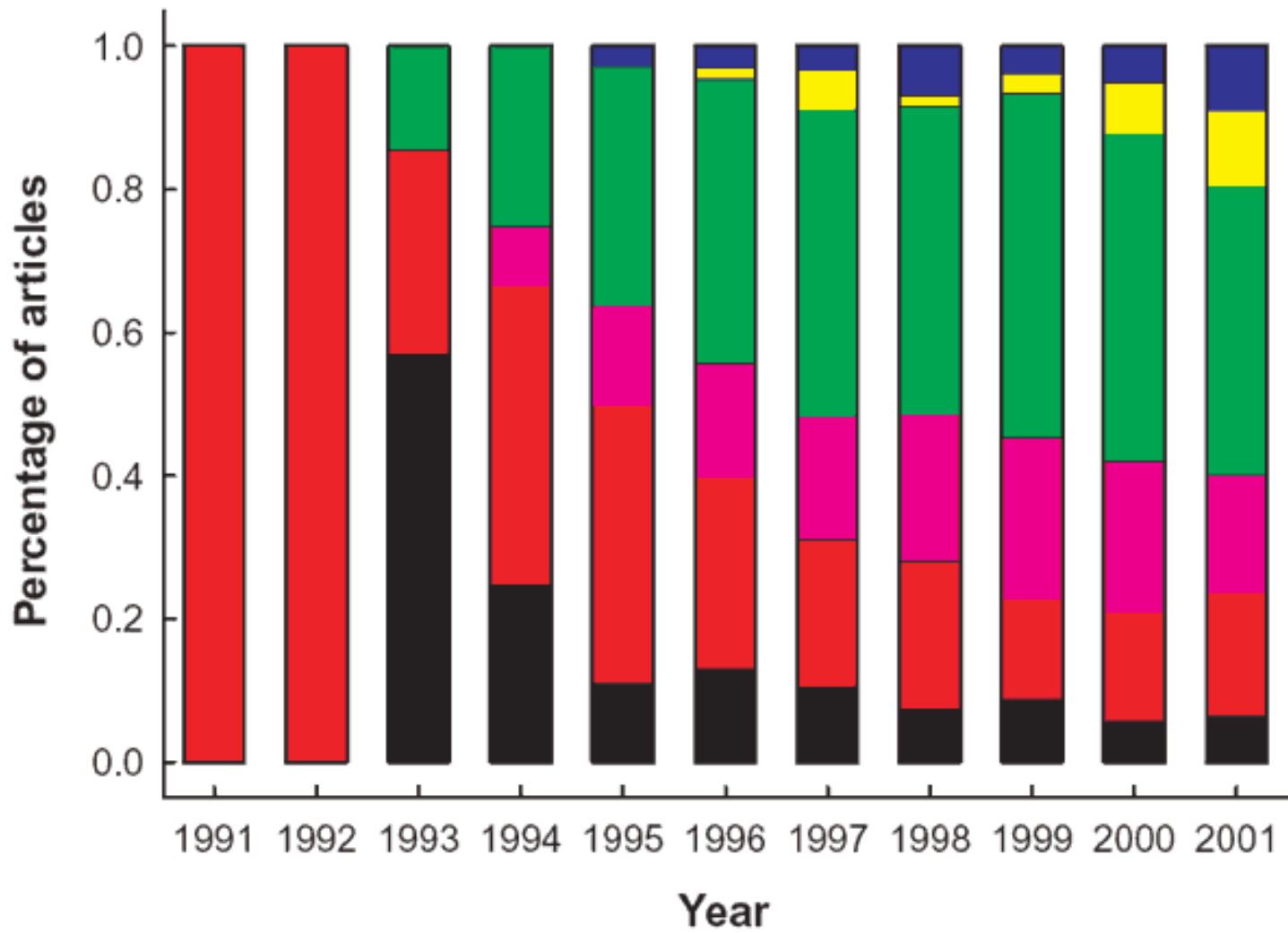


# fMRI Papers Published per Year



"fMRI" or "functional MRI"





**Motor (black)**  
**Primary Sensory (red)**  
**Integrative Sensory (violet)**  
**Basic Cognition (green)**  
**High-Order Cognition (yellow)**  
**Emotion (blue)**

J. Illes, M. P. Kirschen, J.  
 D. E. Gabrielli, *Nature*  
*Neuroscience*, 6 (3) p.205

# Current Uses of fMRI

## Understanding normal brain organization and changes

- networks involved with specific tasks (low to high level processing)
- changes over time (seconds to years)
- correlates of behavior (response accuracy, performance changes...)

## Clinical research

- correlates of specifically activated networks to clinical populations
- presurgical mapping
- epileptic foci mapping
- drug effects

# Potential uses of fMRI

## *Complementary* use for clinical diagnosis

- utilization of clinical research results


## Clinical treatment and assessment

- drug, therapy, rehabilitation, biofeedback

## Non clinical uses

- complementary use with behavioral results
- lie detection
- prediction of behavior tendencies (many contexts)
- brain/computer interface

# A typical day in the fMRI scan room...




1.5 Gbytes/Day  
max: 5.4 Gbytes

# What my group is working on...

Understanding, Developing, and Implementing  
Functional MRI

1. Methodology
2. Interpretation
3. Technology
4. Applications

**Neuronal Activation**



**Measured Signal**



?

**Hemodynamics**

?

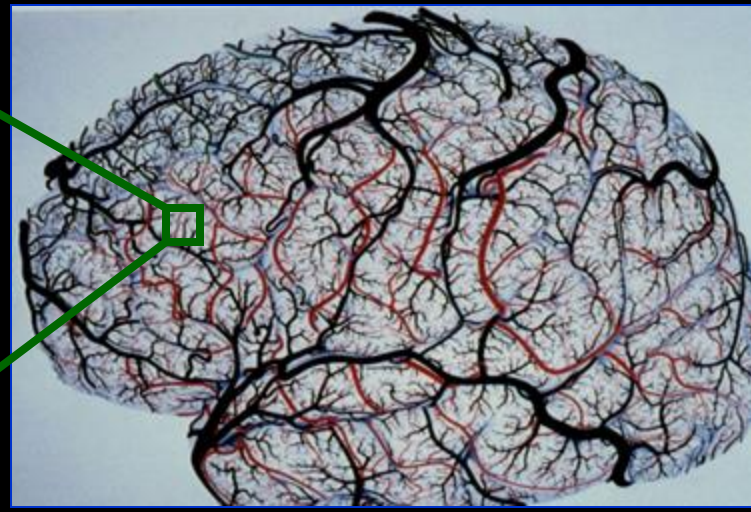
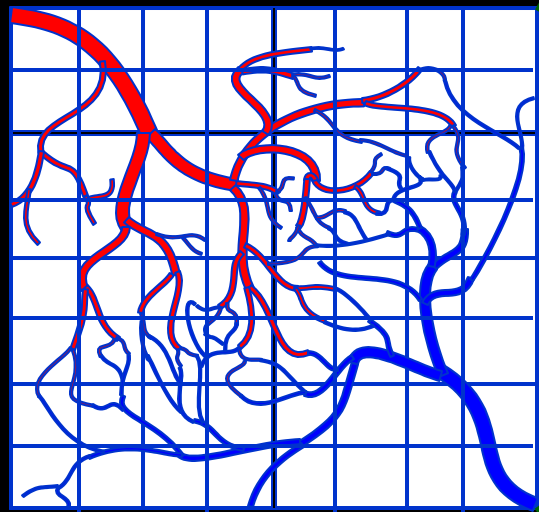

?



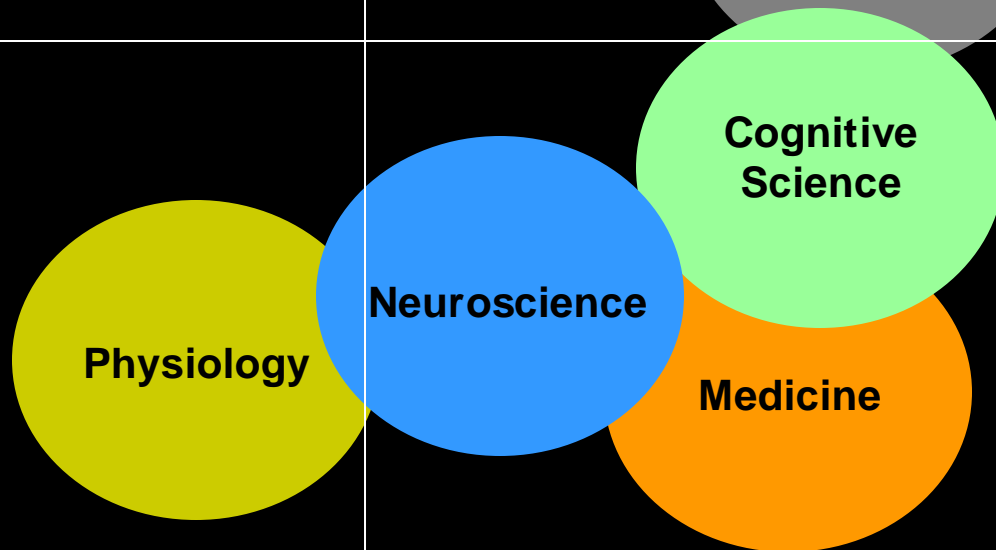
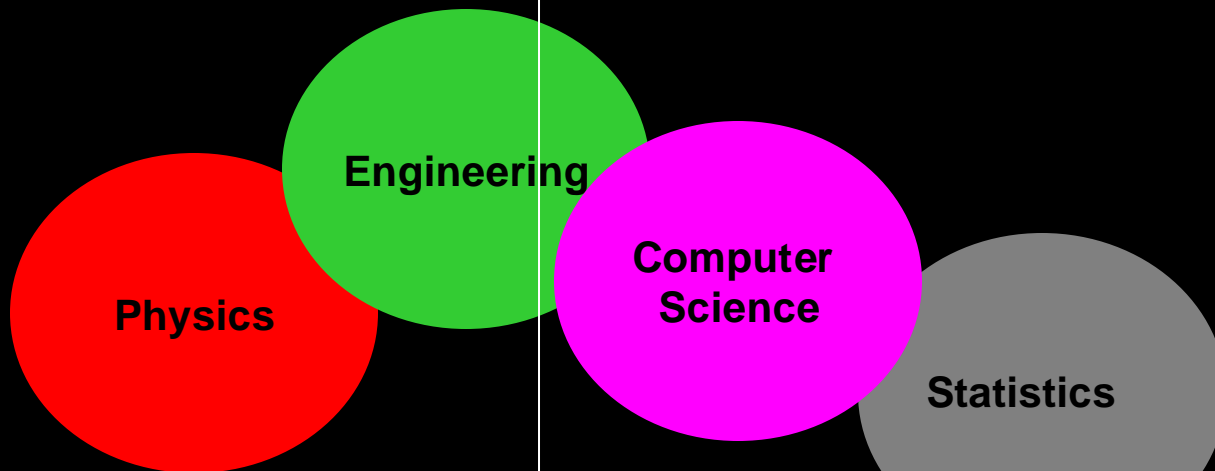
?

**Noise**



**Technology**

**Methodology**



**Interpretation**

**Applications**



# My Group at the NIH

## Section on Functional Imaging Methods

Peter Bandettini (Physics/Physiology/Neuroscience)

Rasmus Birn (Physics)

David Knight (Neuroscience)

Anthony Boemio (Physics/Neuroscience)

Niko Kriegeskorte (Psychology/Statistics)

Monica Smith (Physics)

Najah Waters (Psychology)

Douglass Ruff (Psychology)

David Ruff (Neuroscience)

Marieke Mur (Neuroscience)

## FMRI Core Facility

Jerzy Bodurka (Physics)

Sean Marrett (Neuroscience)

Frank Ye (Physics)

Wen-Ming Luh (Physics)

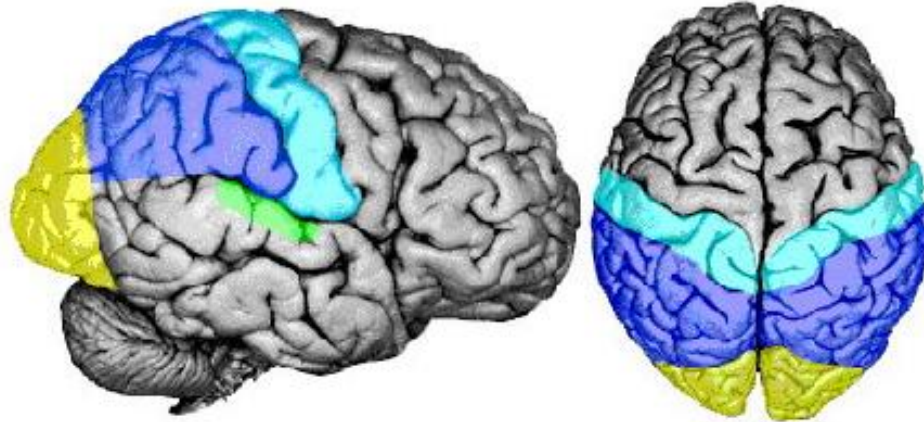
Adam Thomas (Computers/Neurosci)

Karen Bove-Bettis (MR Tech)

Paula Rowser (MR Tech)

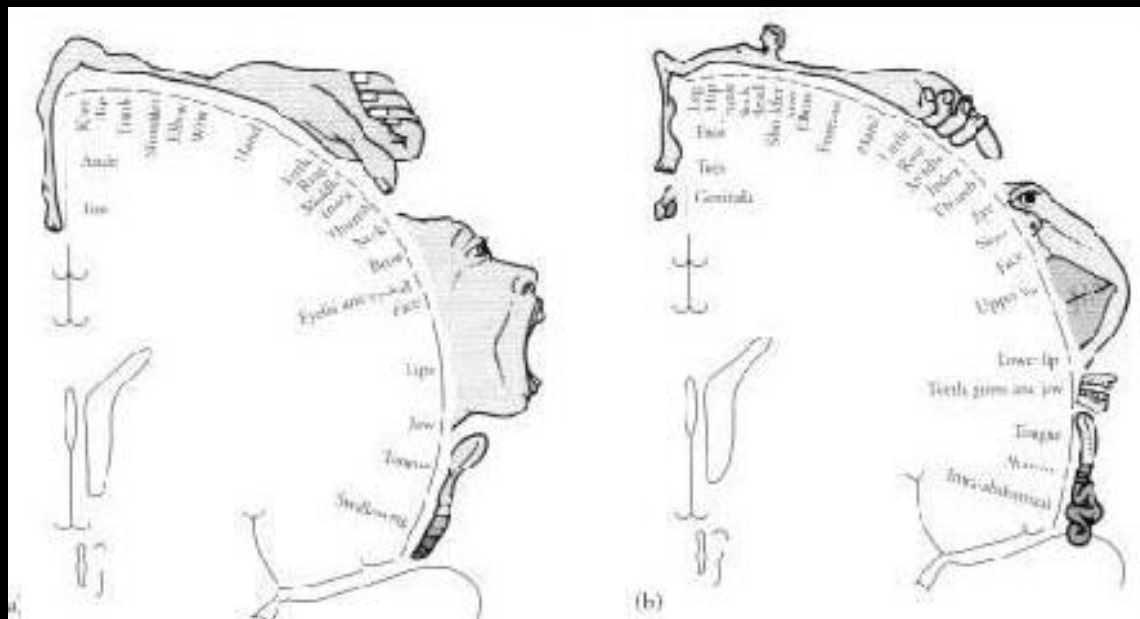
Alda Ottley (MR Tech)

Ellen Condon (MR Tech)



■ Parietal/  
Somatosensory  
■ Parietal/  
Association Area

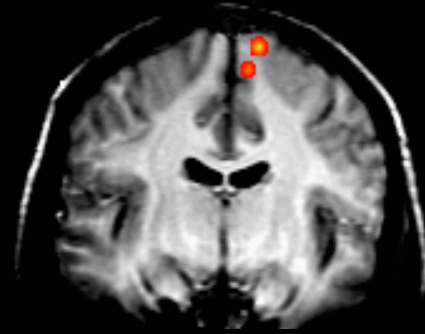
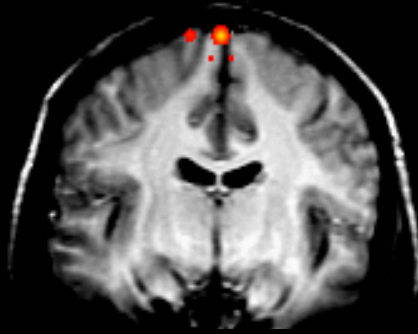
■ Occipital/Vision  
■ Auditory



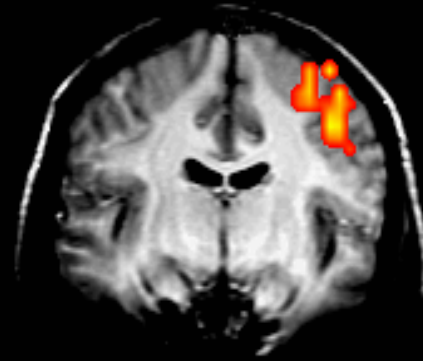
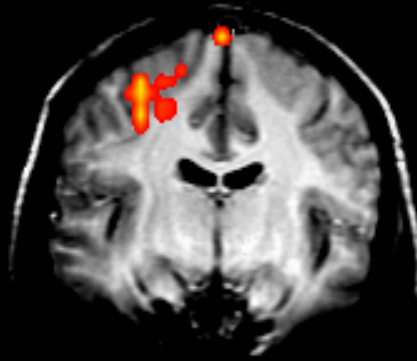
Left

Right

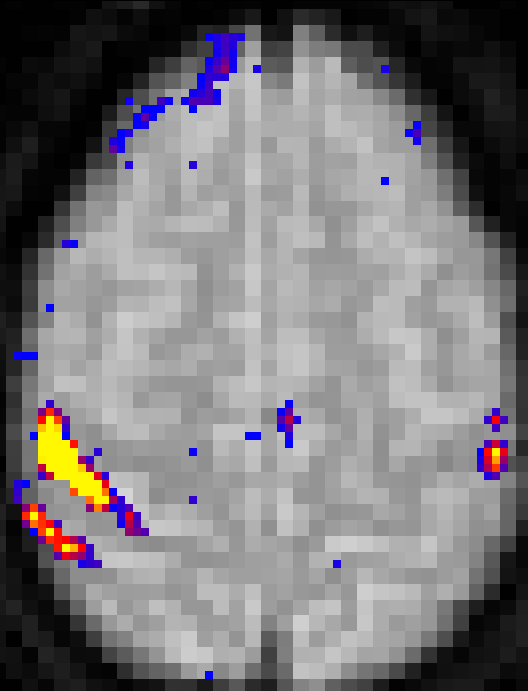
Toe movement



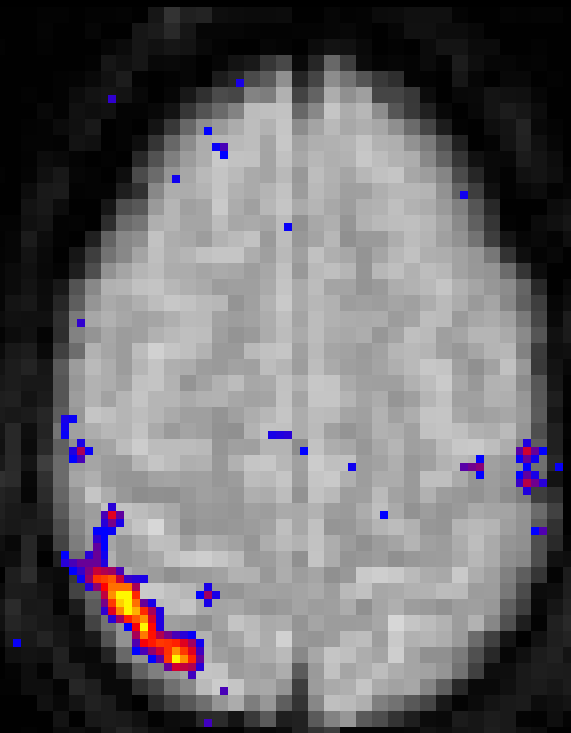
Finger movement



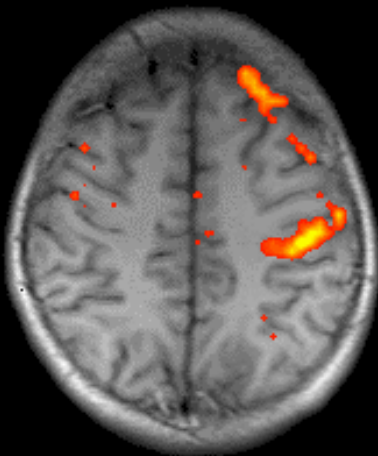
# Finger Movement



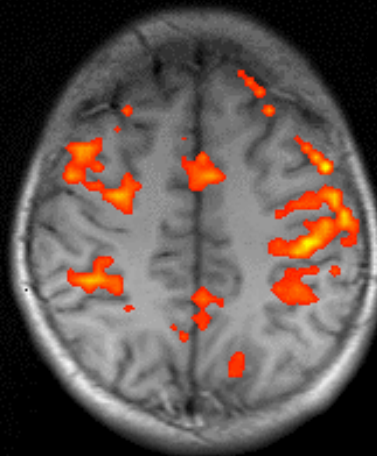
# Tactile Stimulation



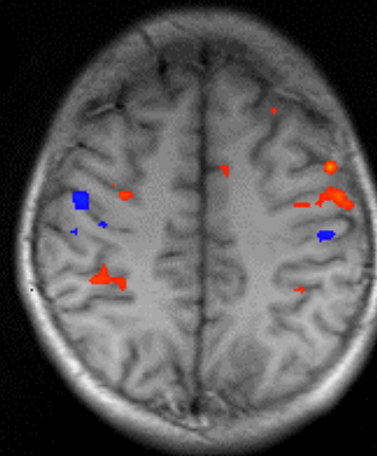
Simple Right



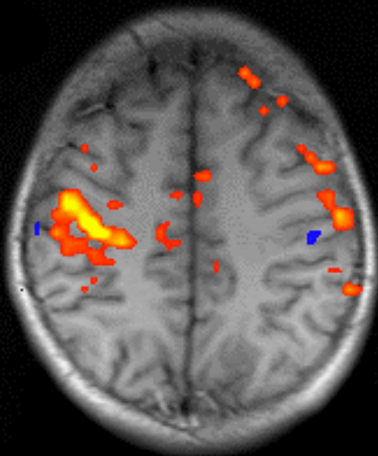
Complex Right



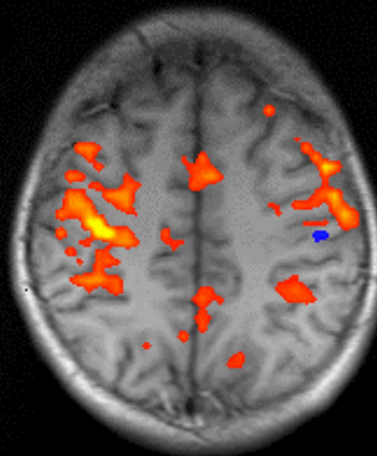
Imagined Complex Right



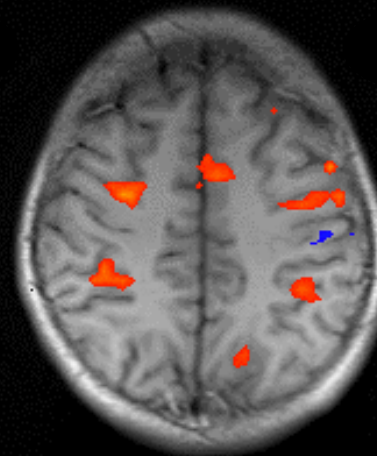
Simple Left



Complex Left

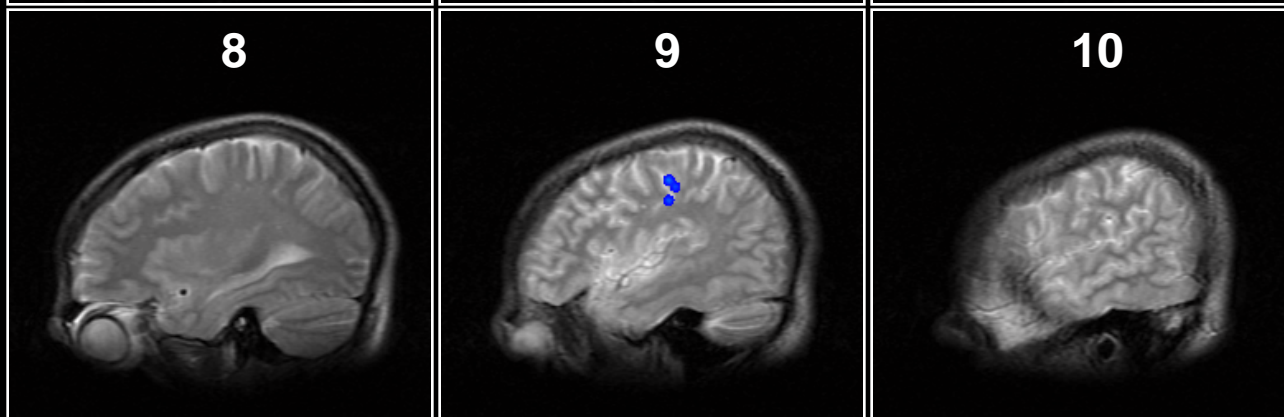
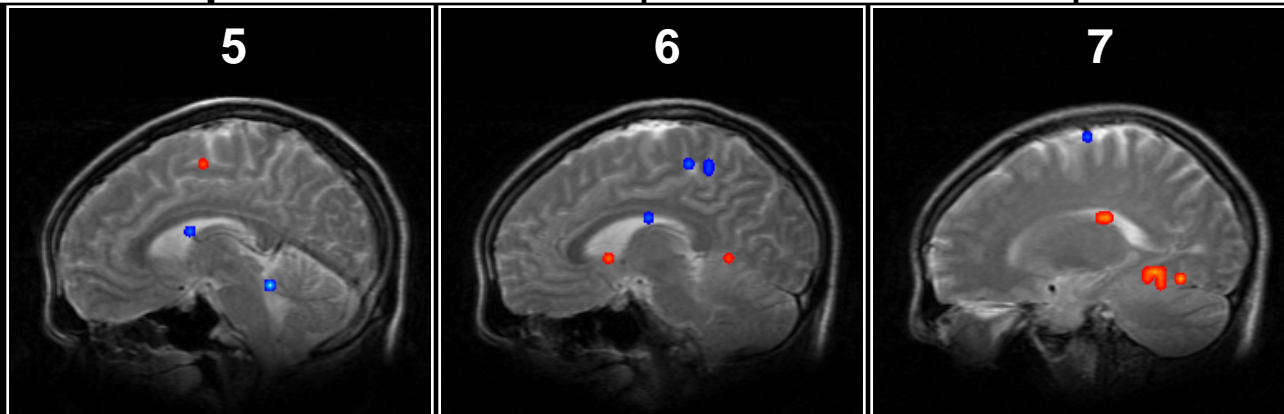
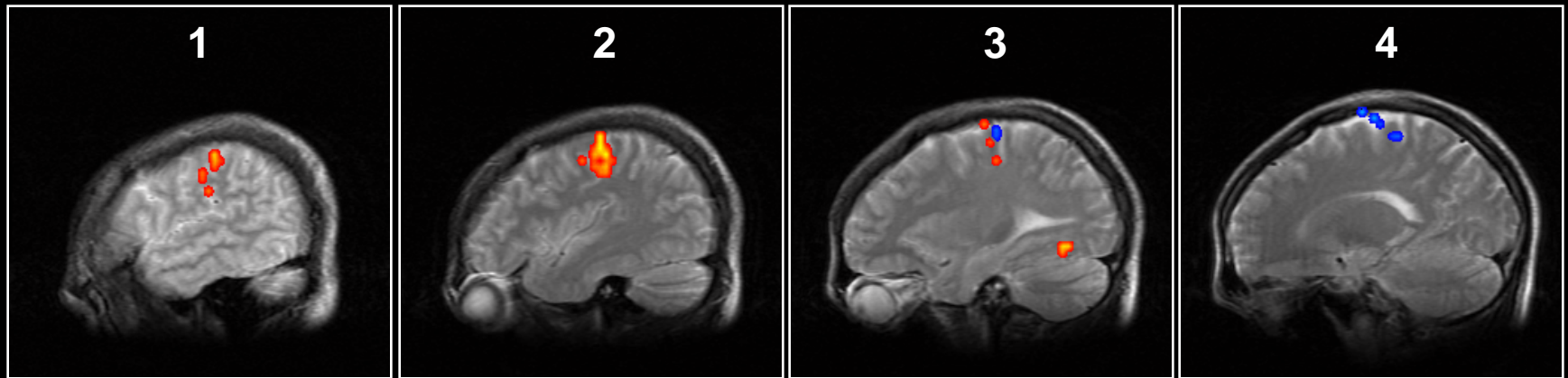


Imagined Complex Left



**Left**

**Simple Finger Movement on the Right Hand**

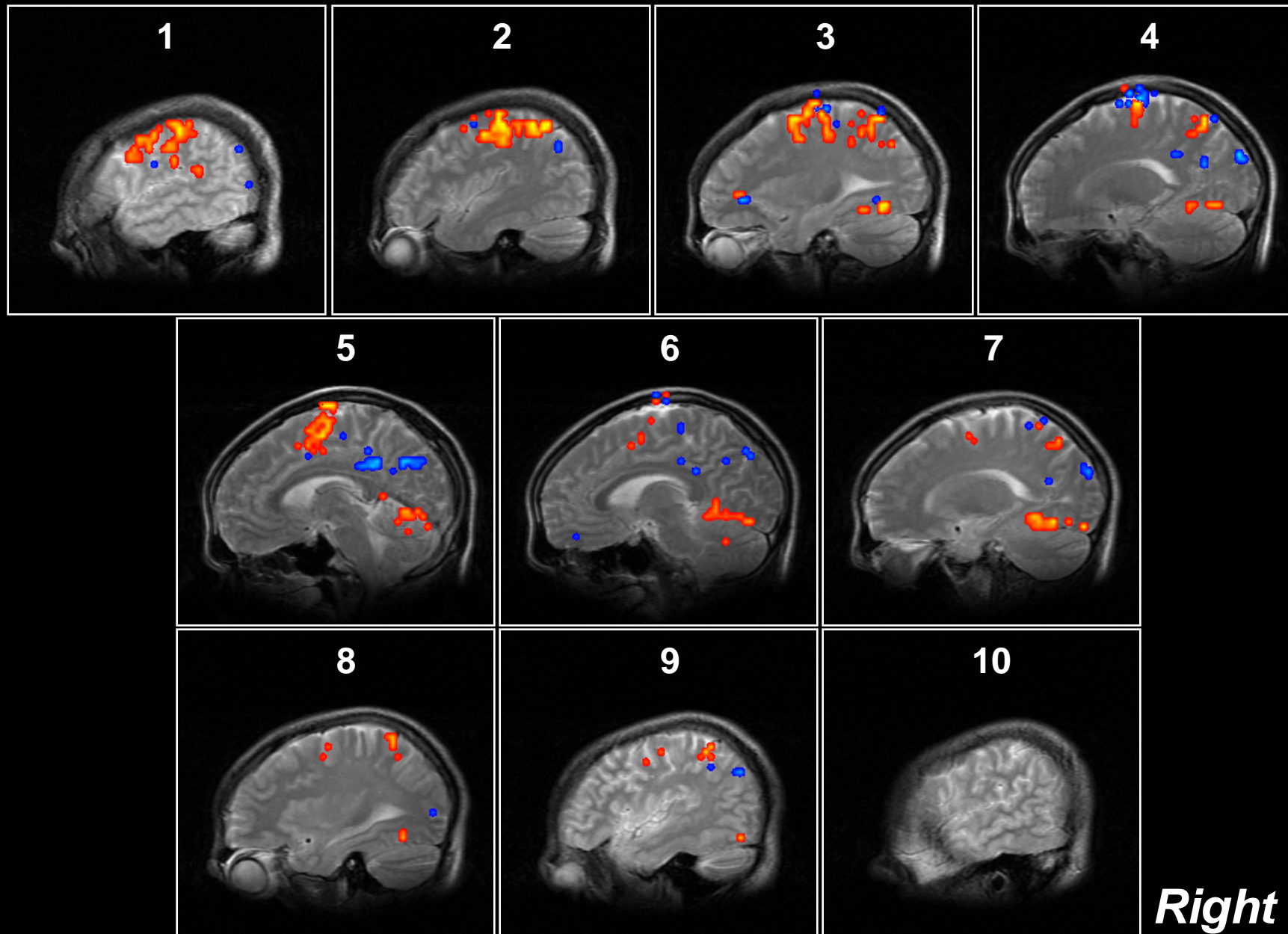


**Right**



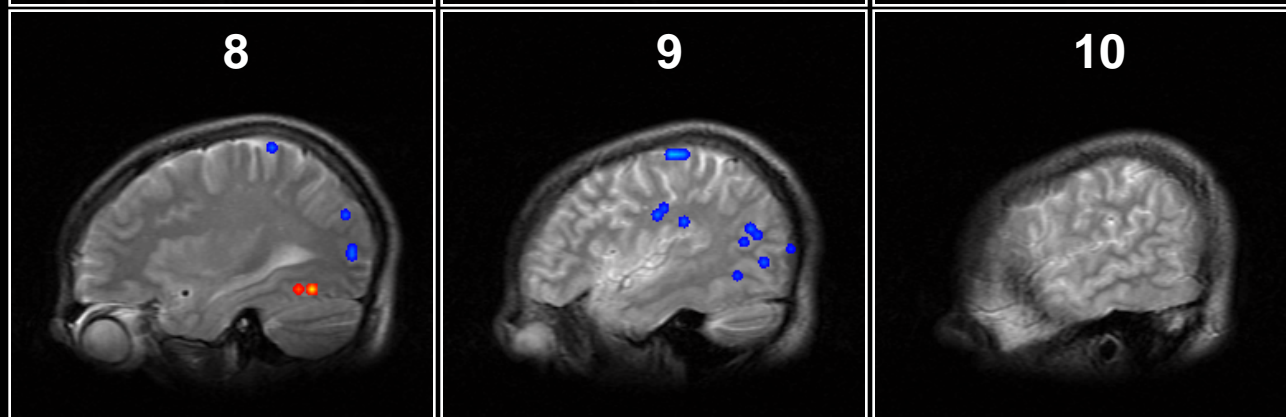
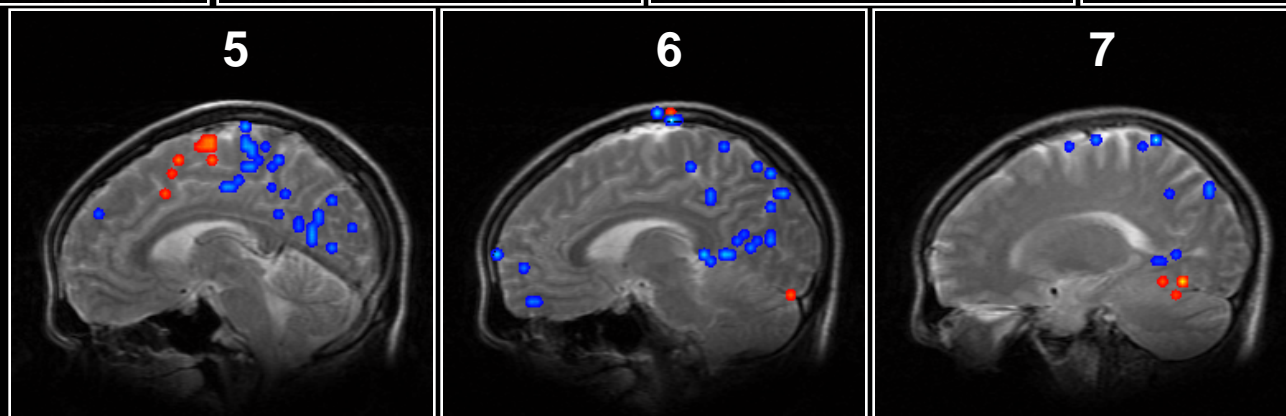
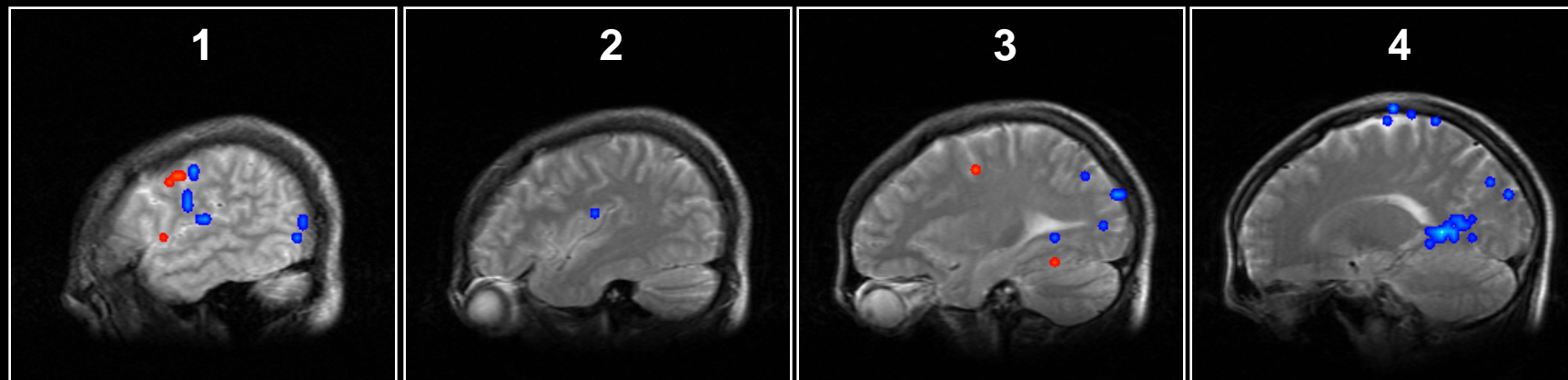
**Left**

**Complex Finger Movement on the Right Hand**



**Left**

**Imagined Complex Finger Movement on the Right Hand**



**Right**

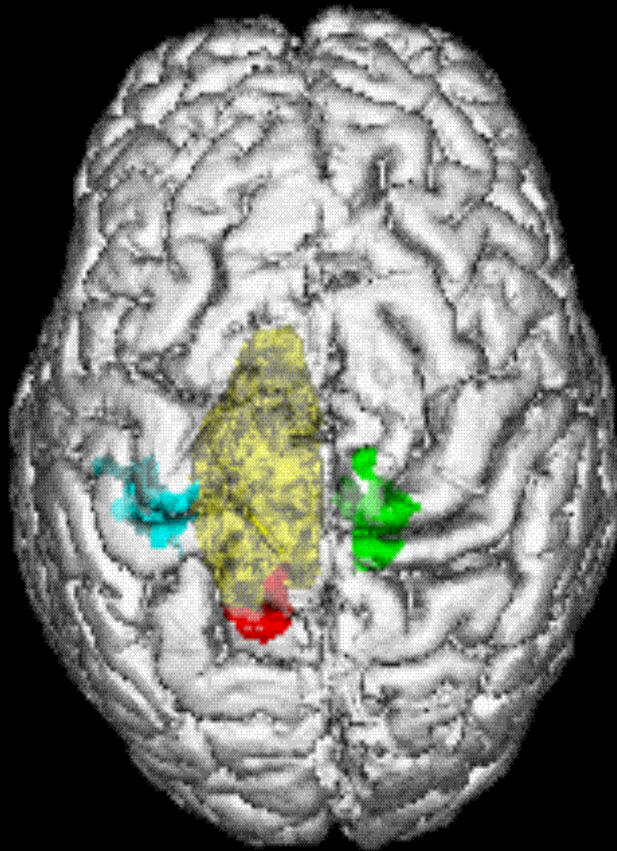
# Presurgical Mapping

Left Foot

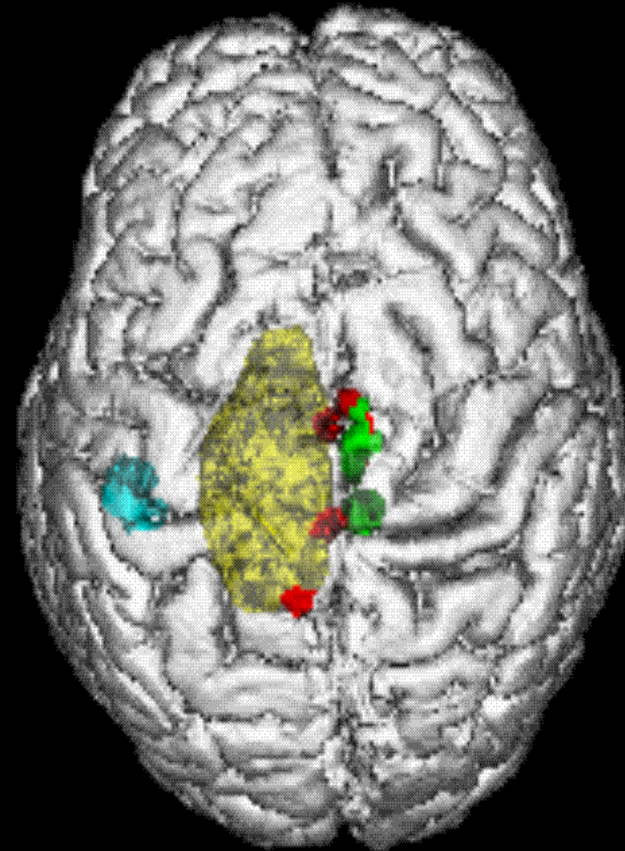
Tumor

Right Foot

Right Hand

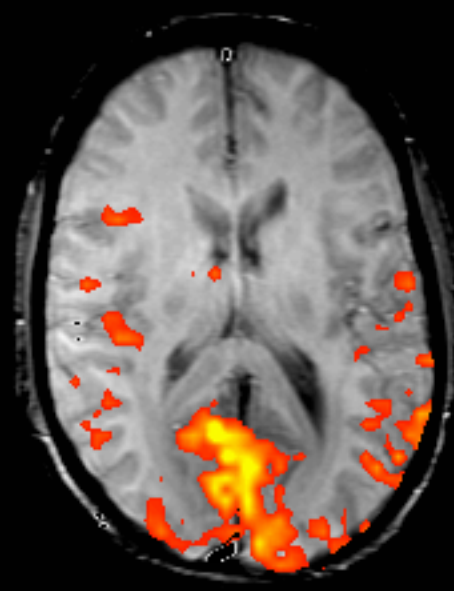
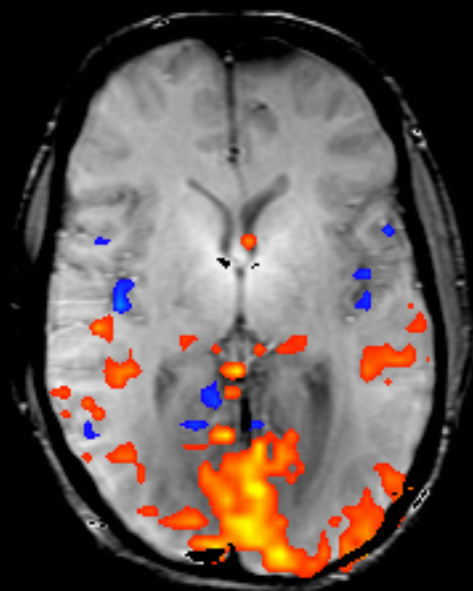


fMRI

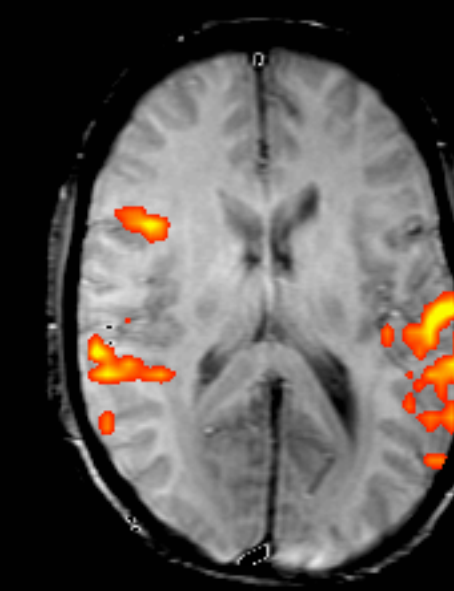
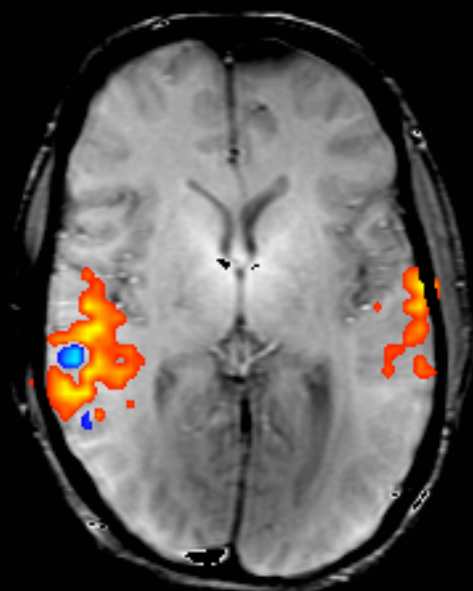


O-15 PET

**Reading**

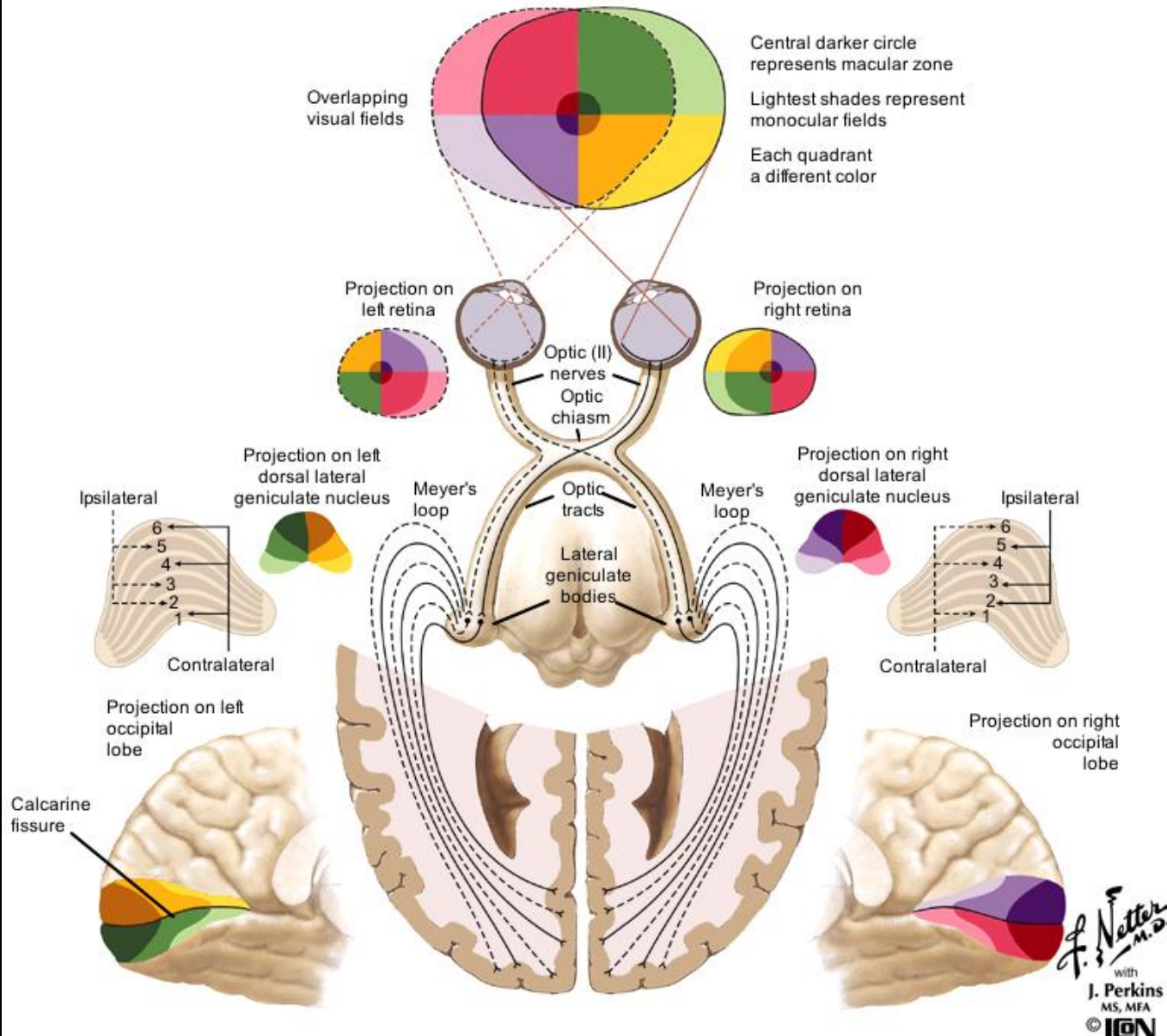


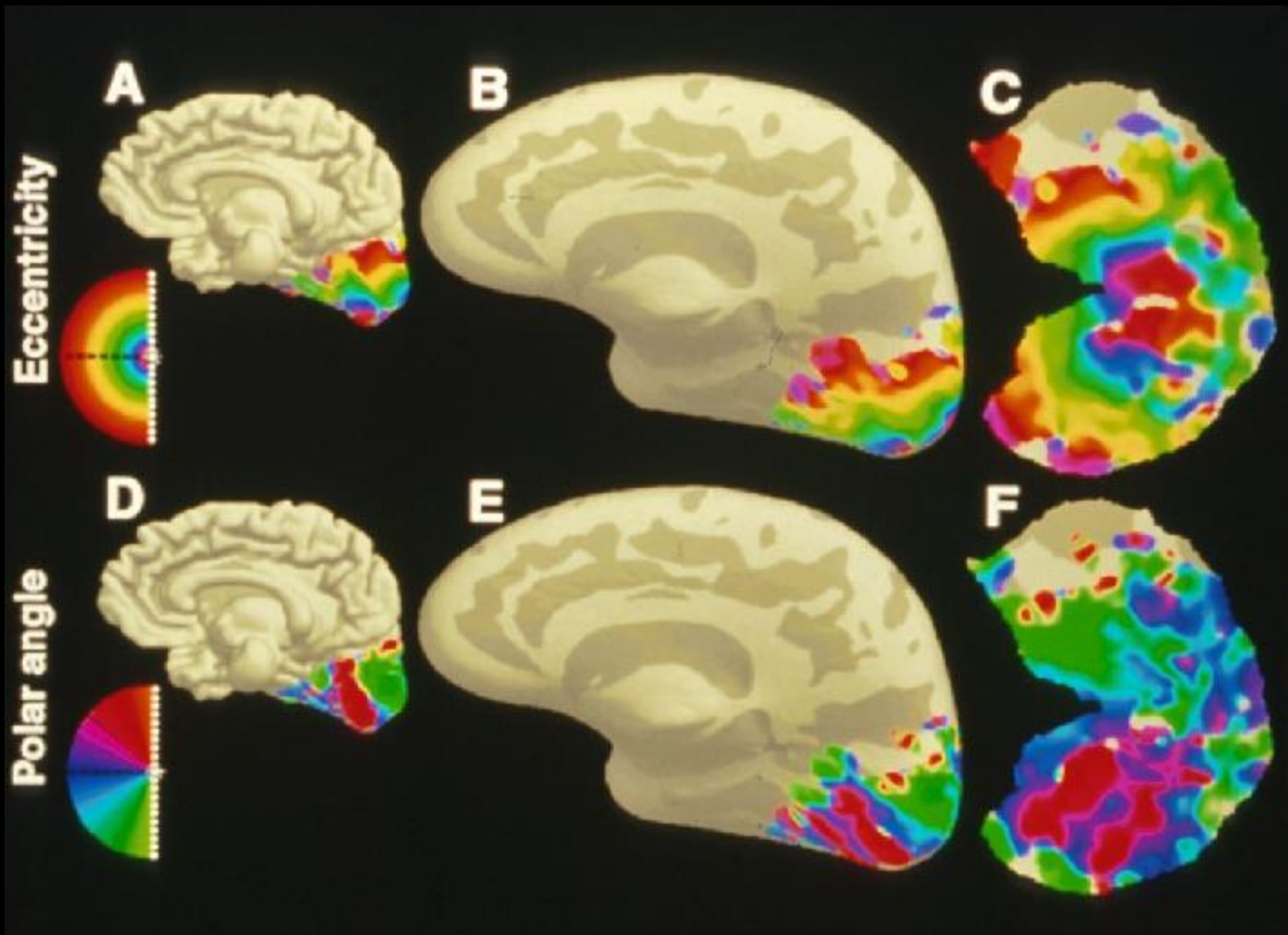
**Listening**





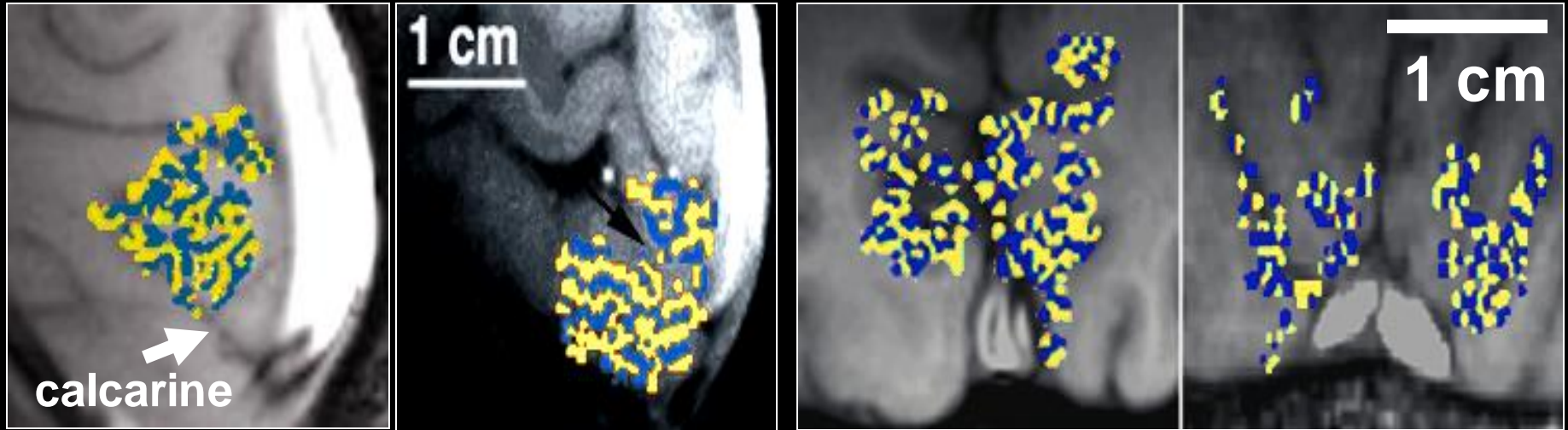
# Visual Pathways: The Retino-Geniculate-Calcarine Pathway







# ODC Maps using fMRI



- Identical in size, orientation, and appearance to those obtained by optical imaging<sup>1</sup> and histology<sup>3,4</sup>.

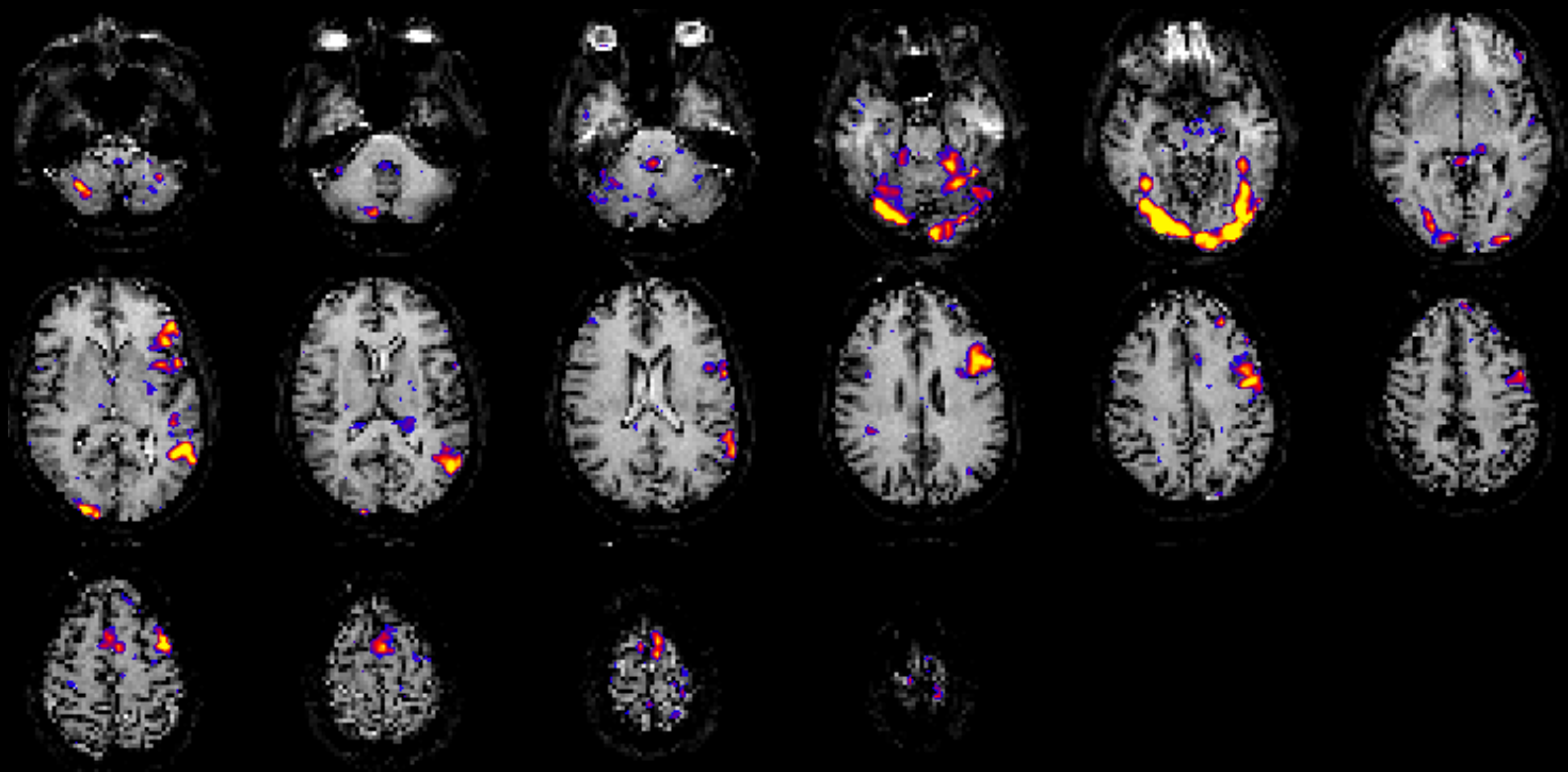
Menon et al.

<sup>1</sup>Malonek D, Grinvald A. *Science* 272, 551-4 (1996).

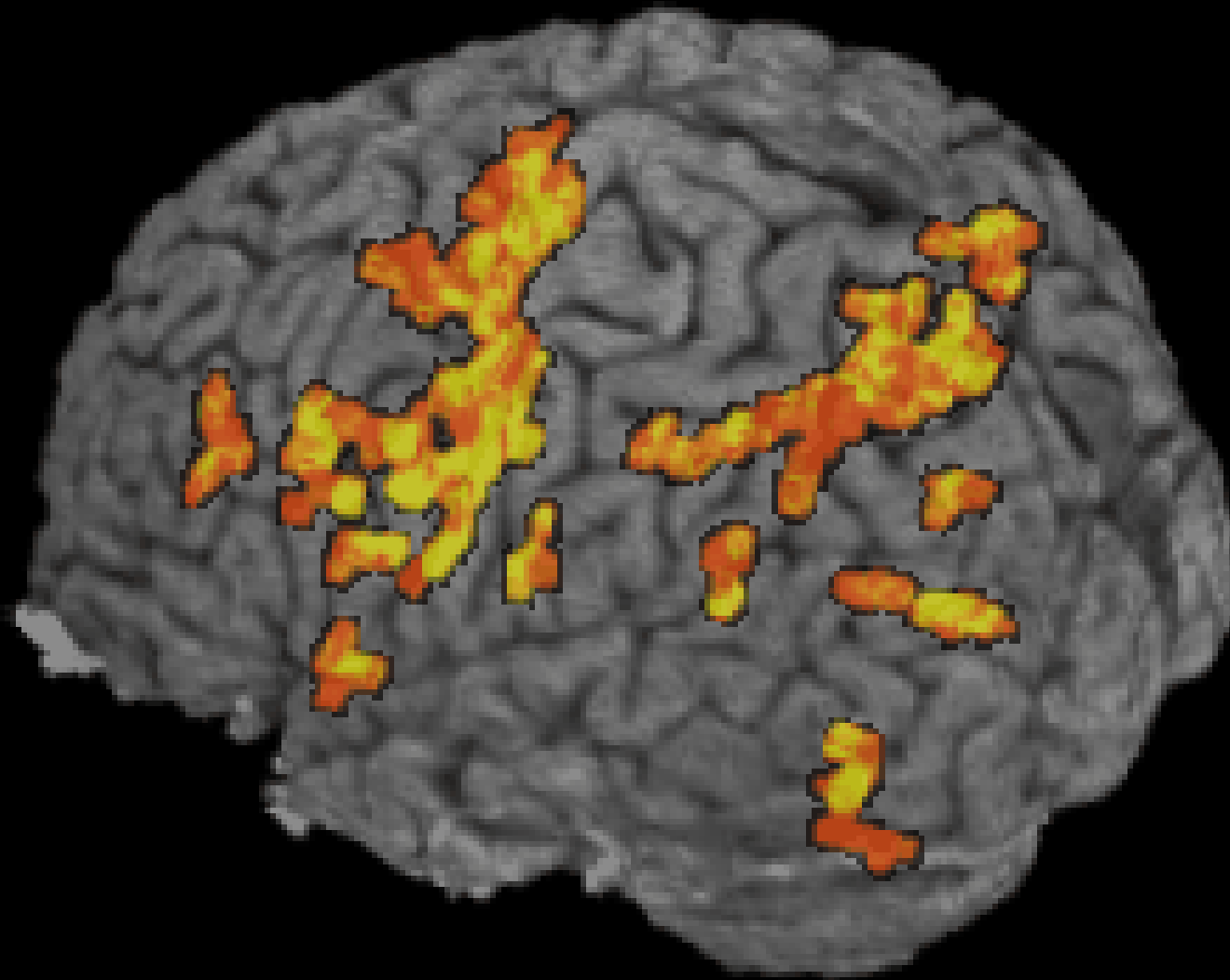
<sup>3</sup>Horton JC, Hocking DR. *J Neurosci* 16, 7228-39 (1996).

<sup>4</sup>Horton JC, et al. *Arch Ophthalmol* 108, 1025-31 (1990).

# Word stem completion



# End of Acquisition



**< 1 s to render**

**Blocked trials:  
20 s on/20 s off  
8 blocks**

**Blocks: 12345678**

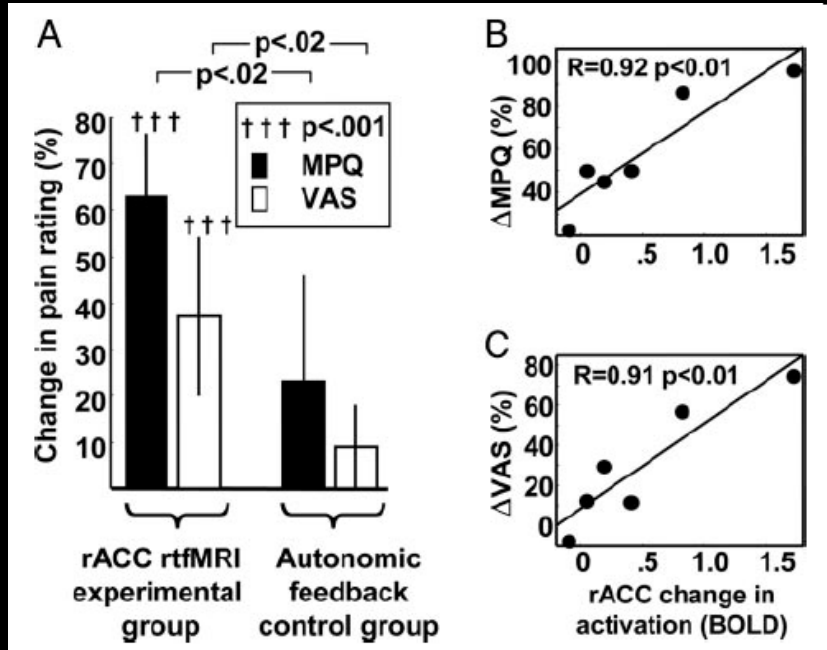
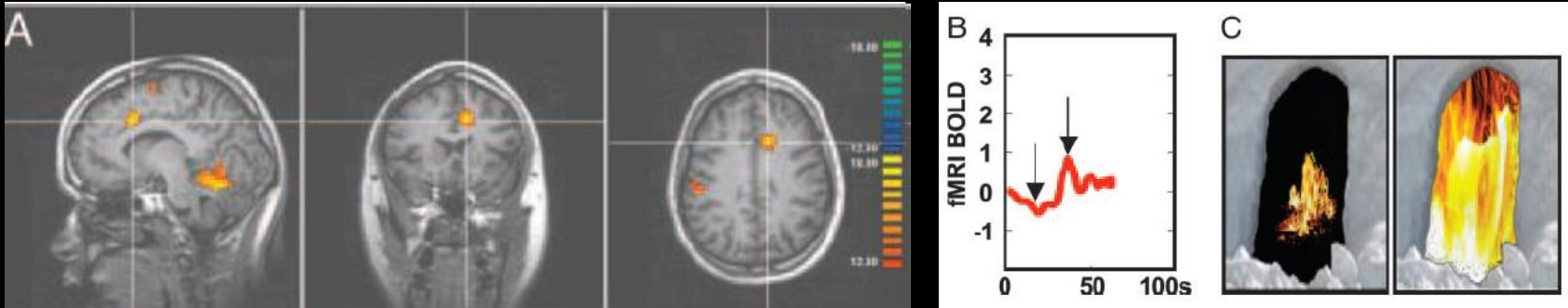
**Color shows  
through brain**

**Correlation > 0.45**

**The  
End**

# Applications

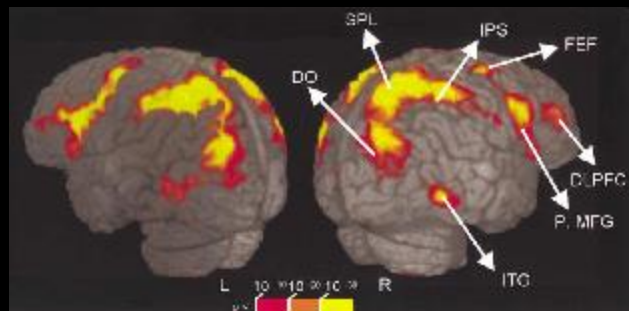
## Real time fMRI feedback to reduce chronic pain



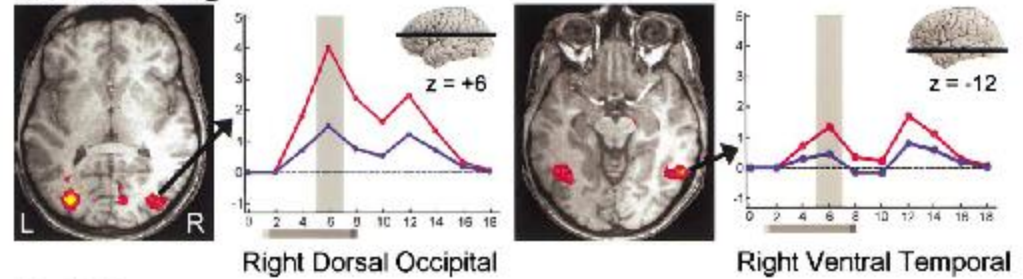
Control over brain activation and pain learned by using real-time functional MRI, R. C. deCharms, et al. PNAS, 102; 18626-18631 (2005)

# Neural Correlates of Visual Working Memory: fMRI Amplitude Predicts Task Performance

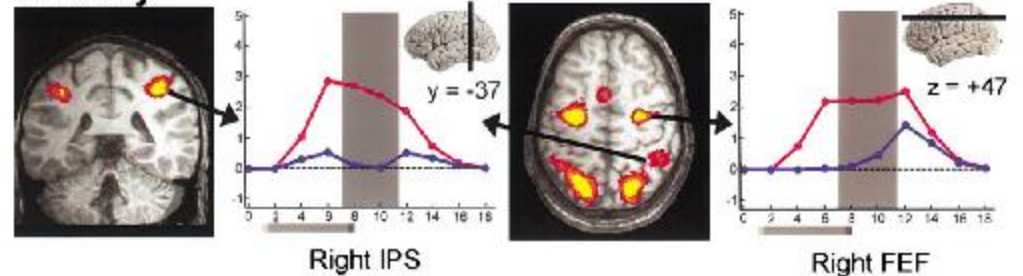
Luiz Pessoa,<sup>1</sup> Eva Gutierrez, Peter A. Bandettini,  
and Leslie G. Ungerleider  
Laboratory of Brain and Cognition  
National Institute of Mental Health  
National Institutes of Health  
Bethesda, Maryland 20892



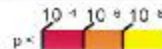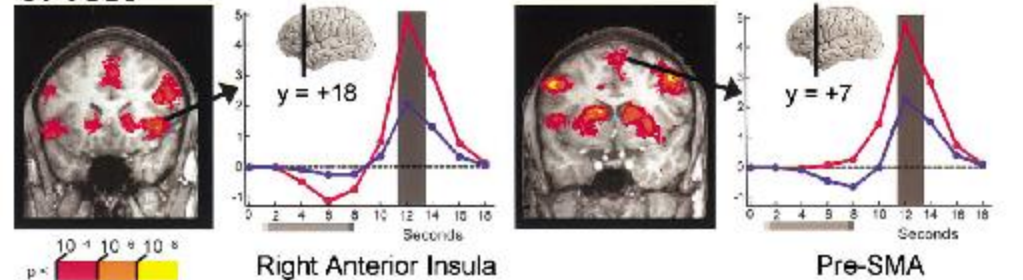
## A. Encoding



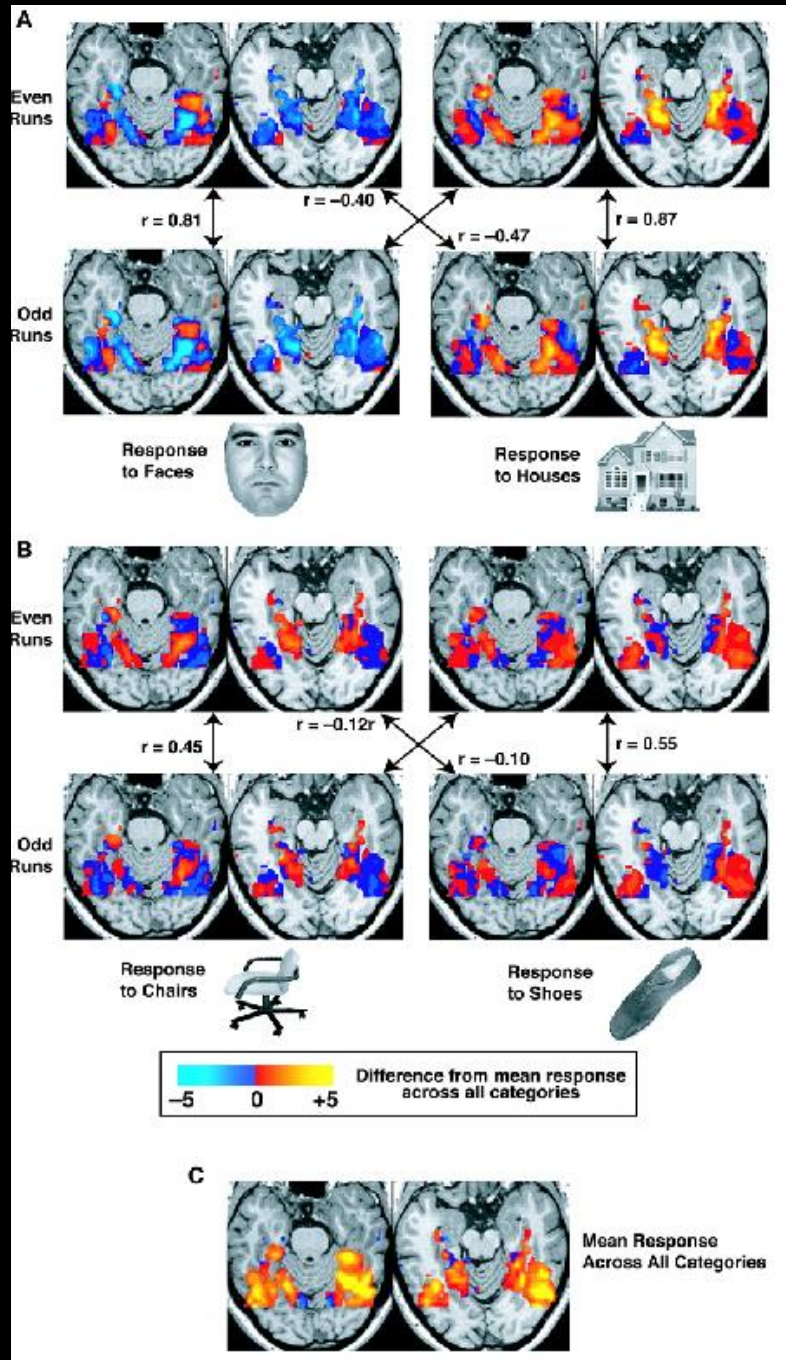
## B. Delay



## C. Test







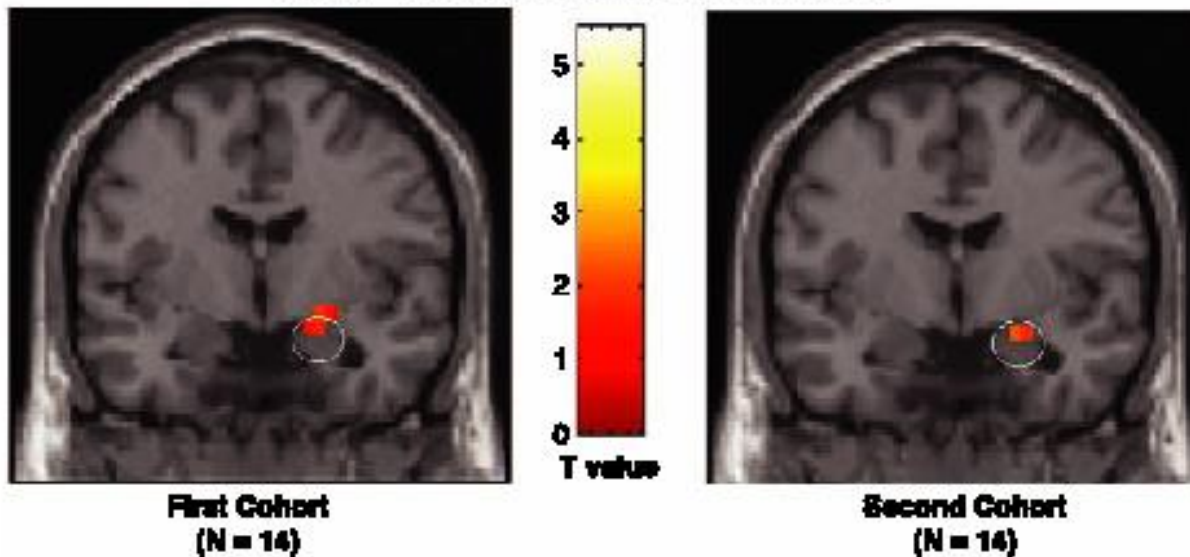
Haxby et al (2001)



# Serotonin Transporter Genetic Variation and the Response of the Human Amygdala

Ahmad R. Hariri,<sup>1</sup> Venkata S. Mattay,<sup>1</sup> Alessandro Tessitore,<sup>1</sup>  
Bhaskar Kolachana,<sup>1</sup> Francesco Fera,<sup>1</sup> David Goldman,<sup>2</sup>  
Michael F. Egan,<sup>1</sup> Daniel R. Weinberger<sup>1\*</sup>

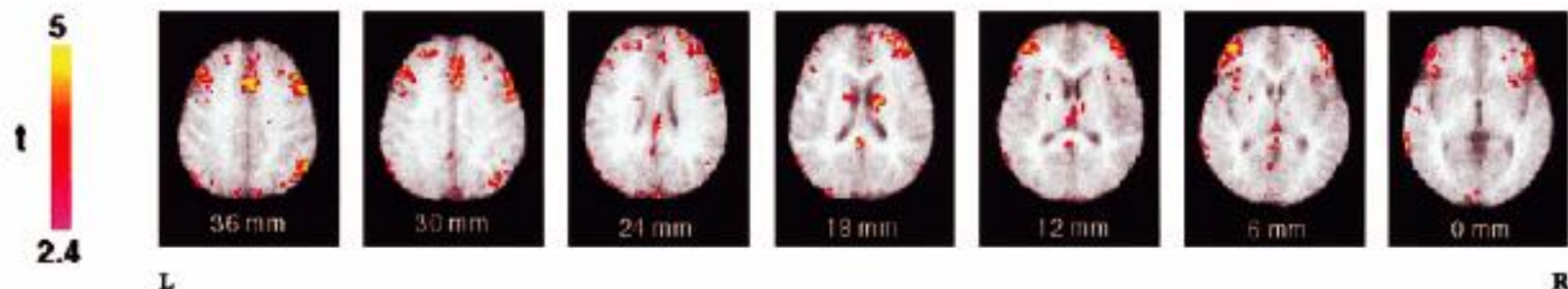
## Amygdala Response: 2 Group > 1 Group



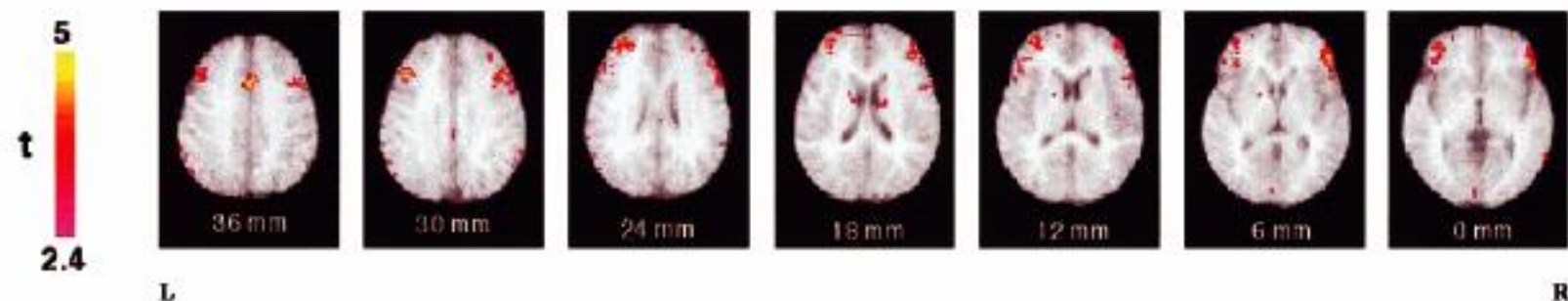
## Lie Detection by Functional Magnetic Resonance Imaging

Tatia M.C. Lee,<sup>1\*</sup> Ho-Ling Liu,<sup>2</sup> Li-Hai Tan,<sup>3</sup> Chetwyn C.H. Chan,<sup>4</sup>  
Srikanth Mahankali,<sup>5</sup> Ching-Mei Feng,<sup>5</sup> Jinwen Hou,<sup>5</sup>  
Peter T. Fox,<sup>5</sup> and Jia-Hong Gao<sup>5</sup>

(a) Digit Memory Task



(b) Autobiographic Memory Task

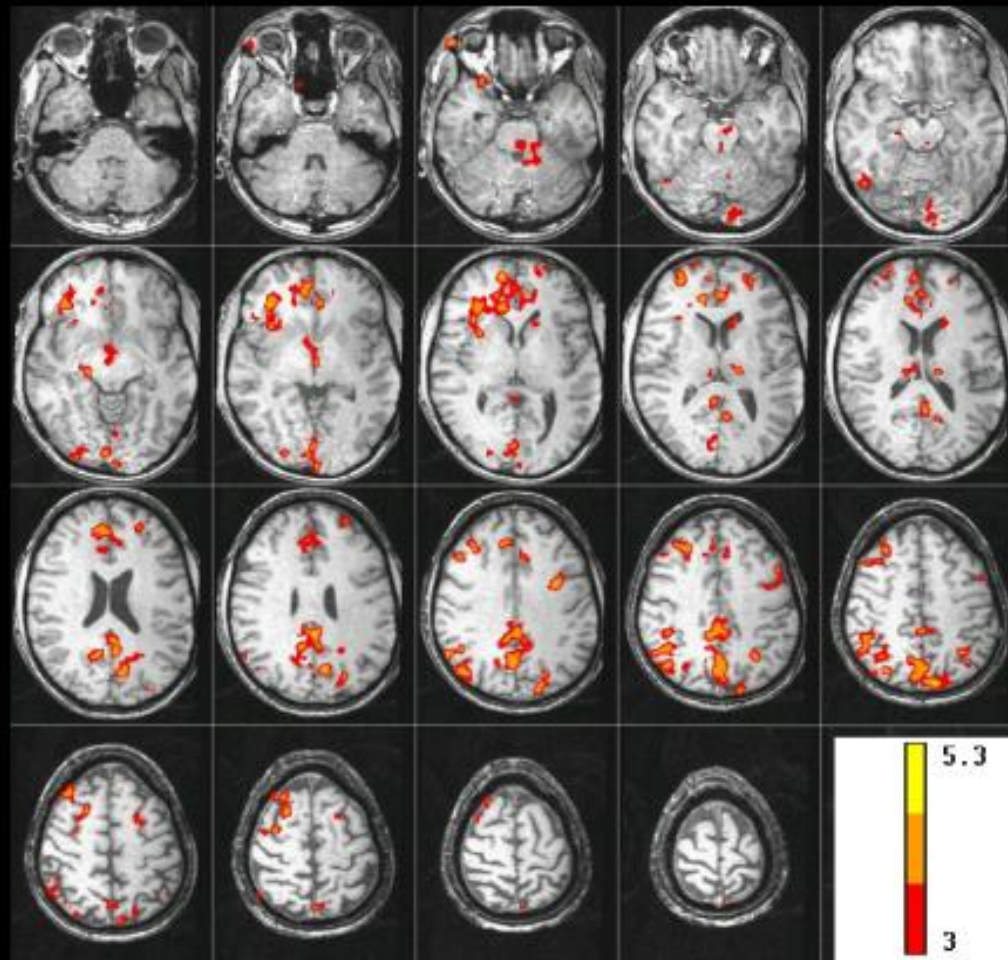


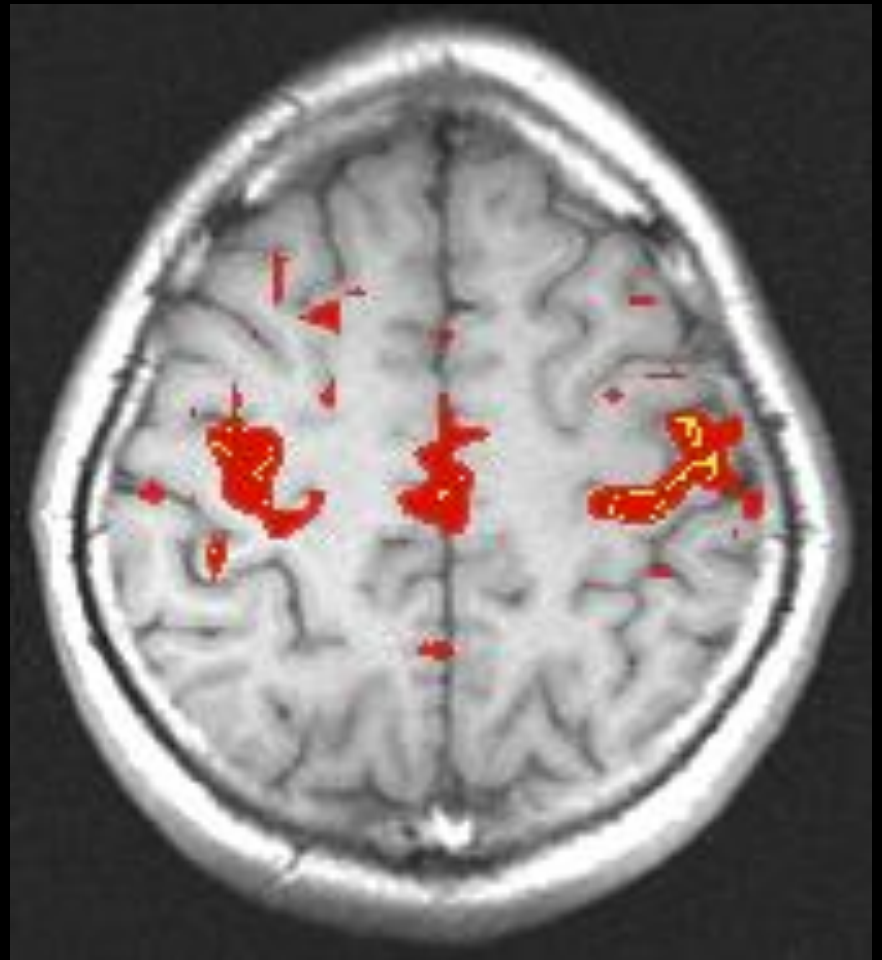
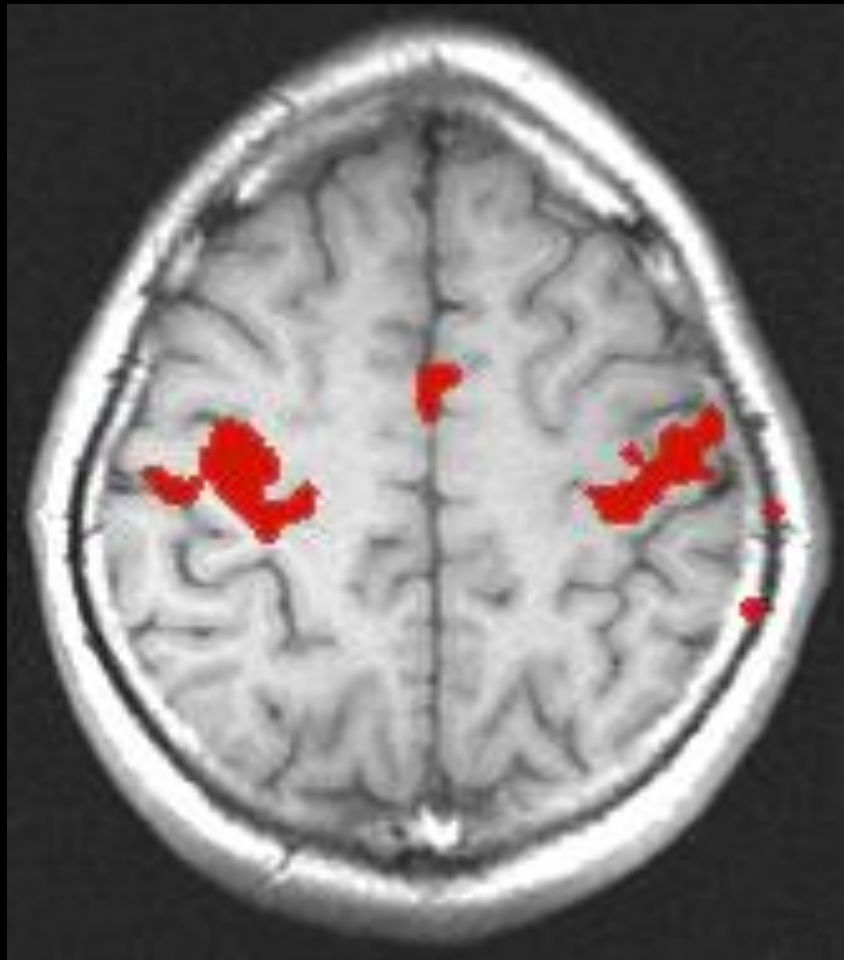
**Figure 1.**

Functional maps. Normalized activation brain maps averaged across five subjects demonstrating the statistically significant activations ( $P < 0.01$ ) in the faking memory impairment condition with the activation for making accurate recall removed when perform-

ing on forced choice testing using (a) Digit Memory and (b) Autobiographic Memory tasks. Planes are axial sections, labeled with the height (mm) relative to the bicommissural line. L, left hemisphere; R, right hemisphere.

# Activation in the brain correlated with skin conductance changes

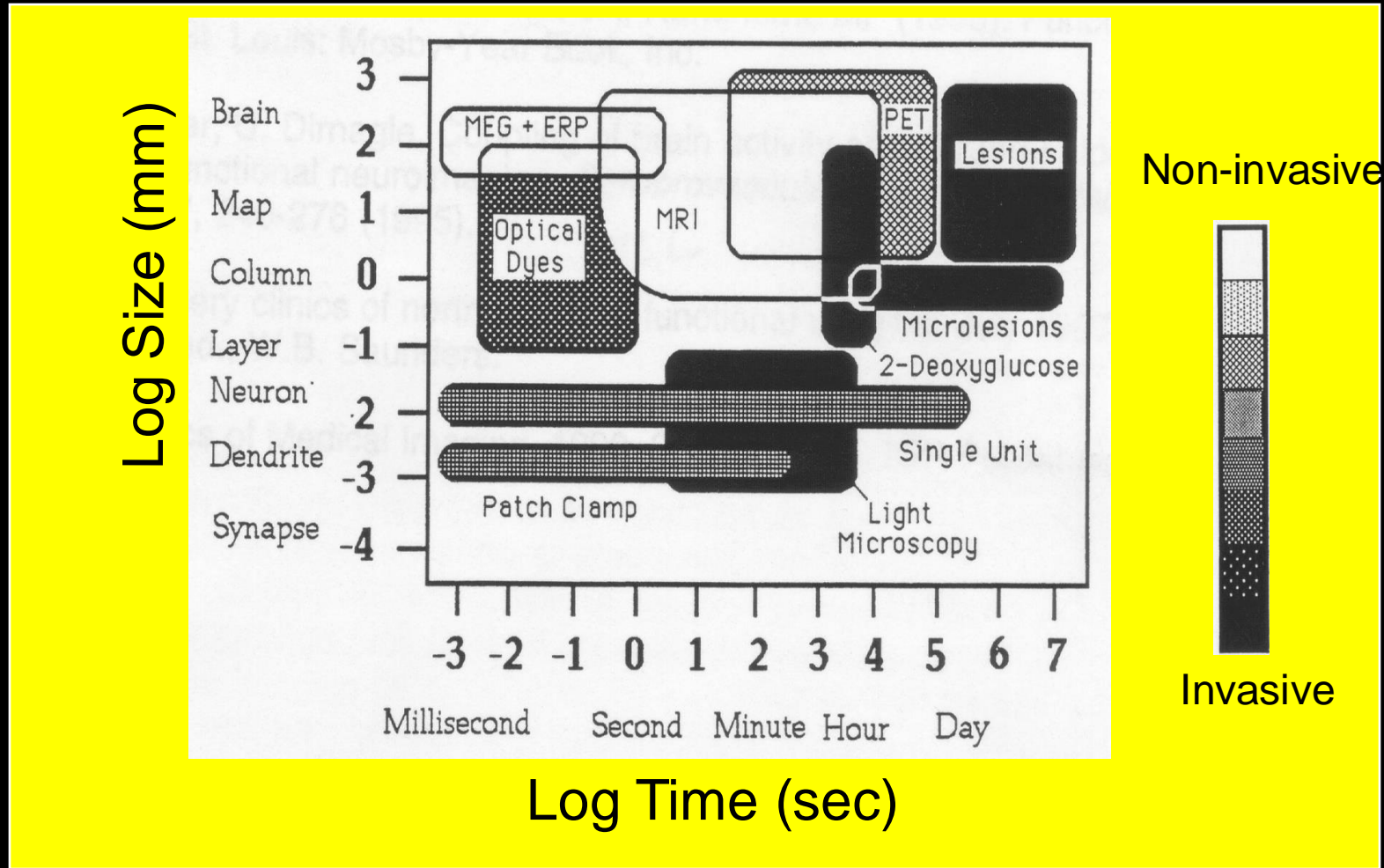




**Biswal, et al (1995), MRM 34, 537-541**



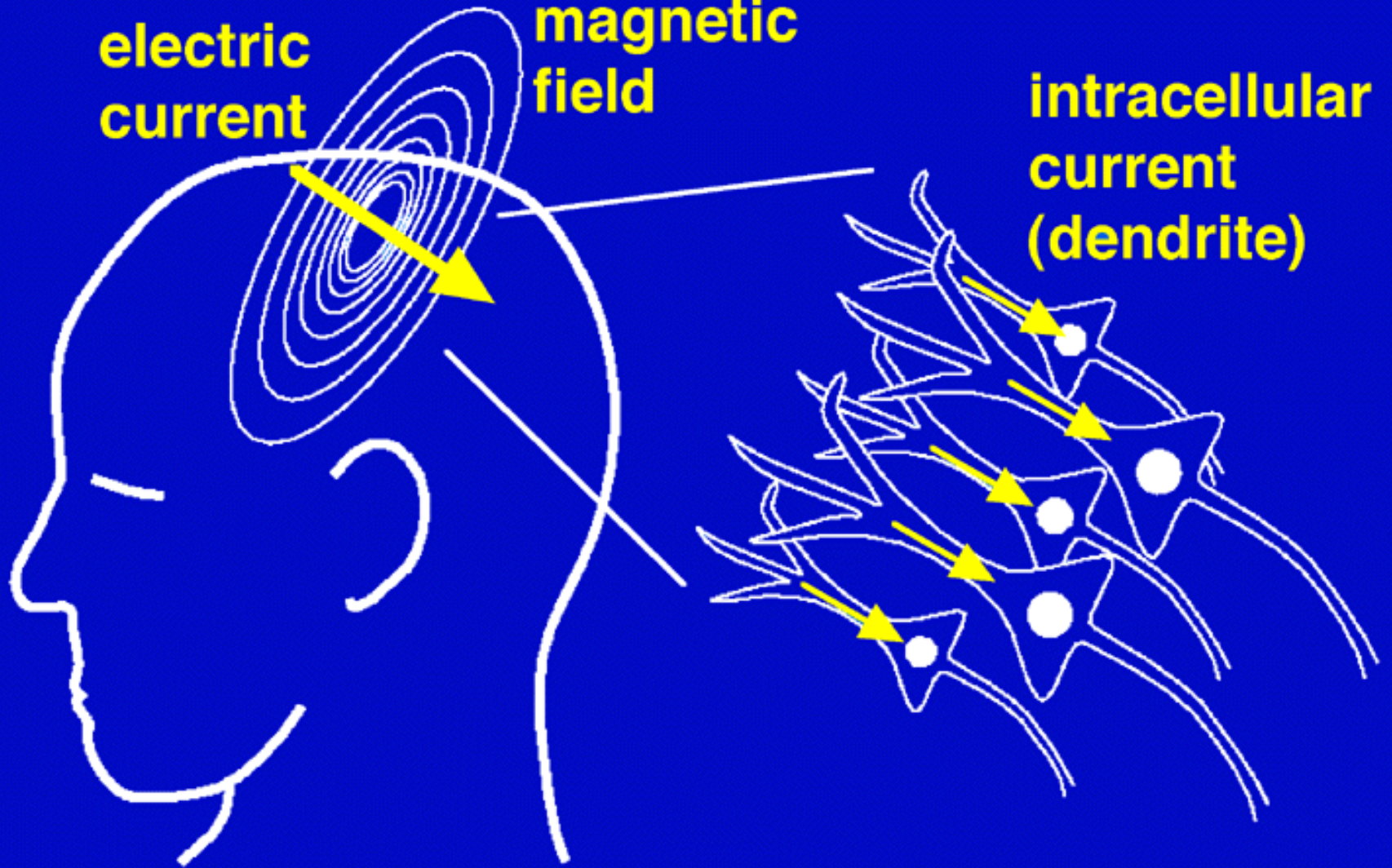
# Functional Neuroimaging Techniques



**electric  
current**

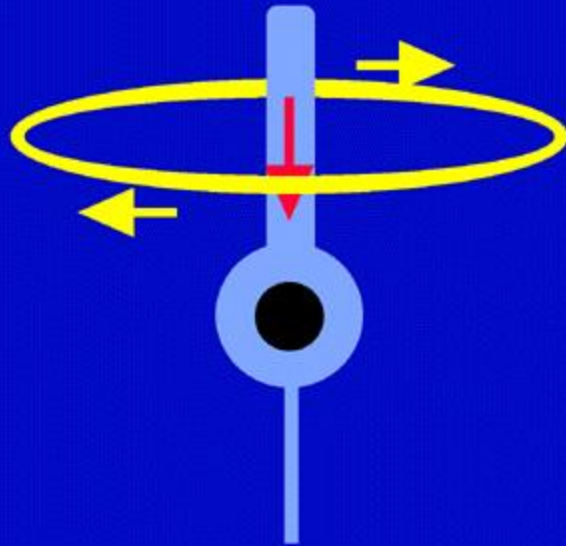
**magnetic  
field**

**intracellular  
current  
(dendrite)**

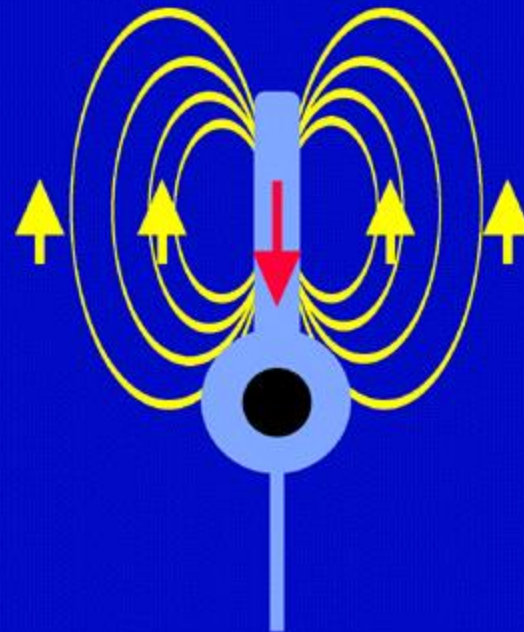




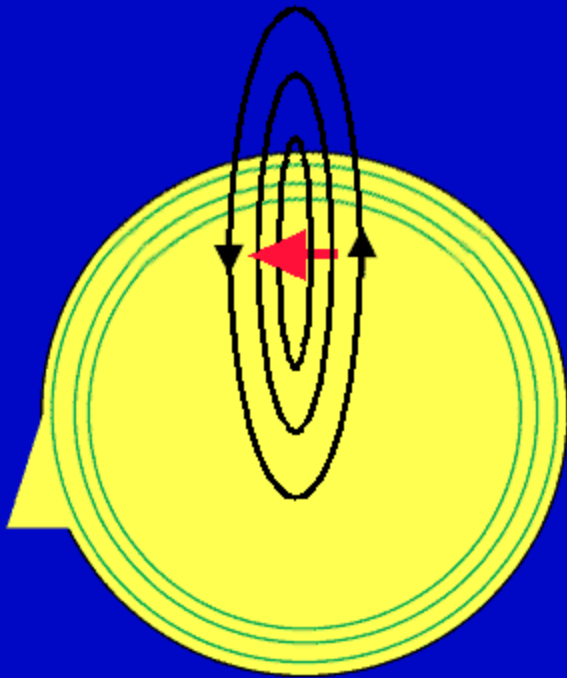
**MEG:**  
intracellular  
current



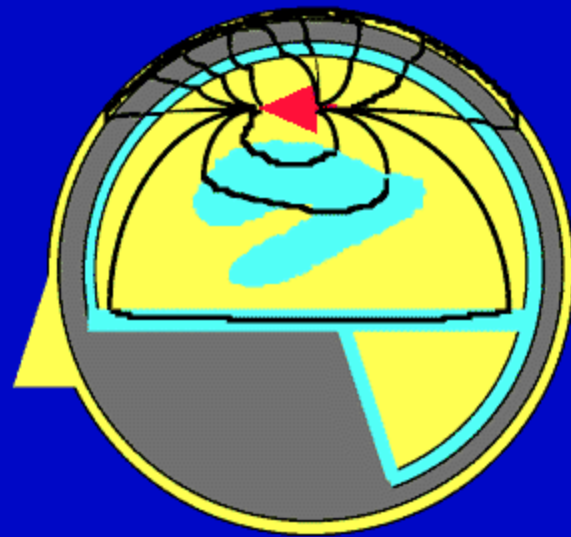
**EEG:**  
extracellular  
current



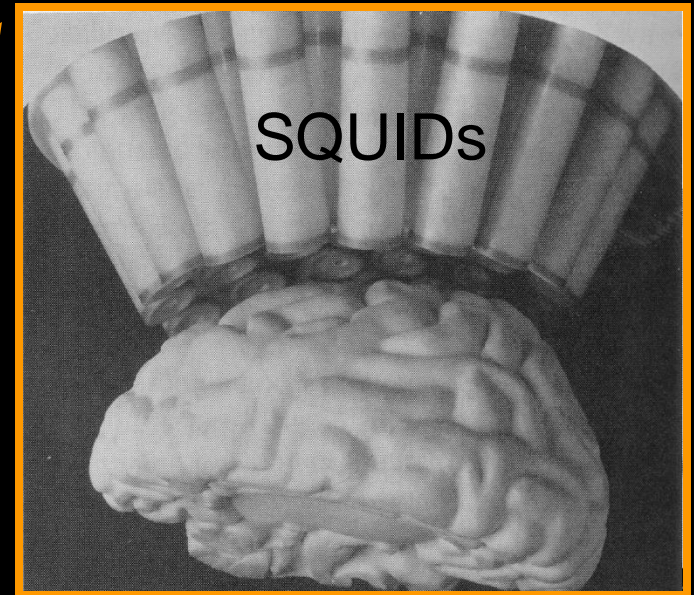
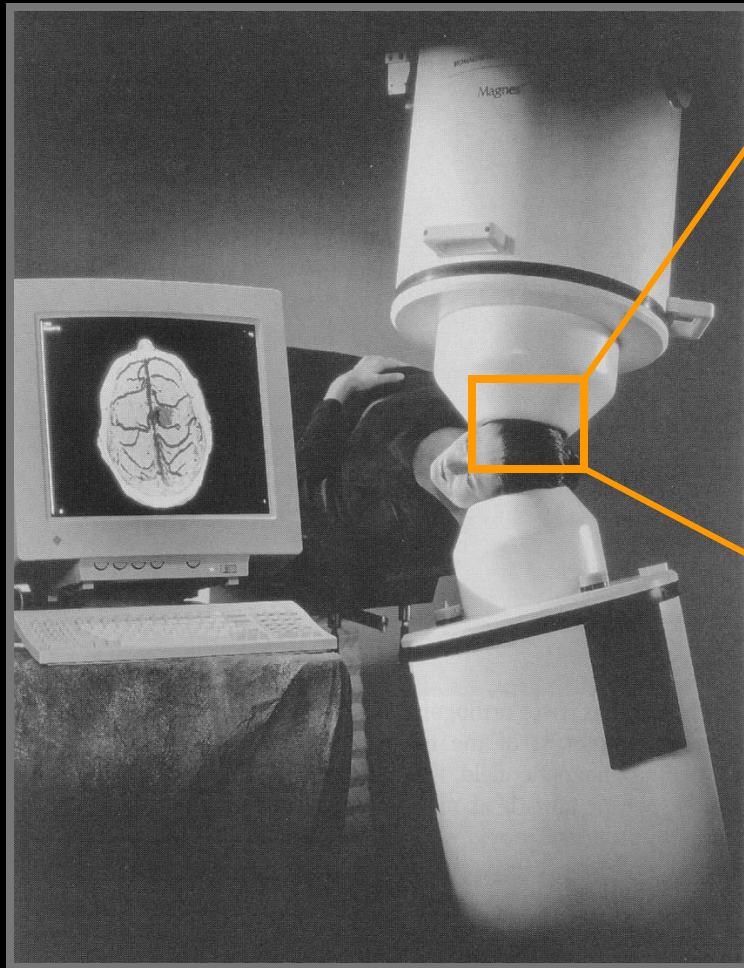
**MEG**



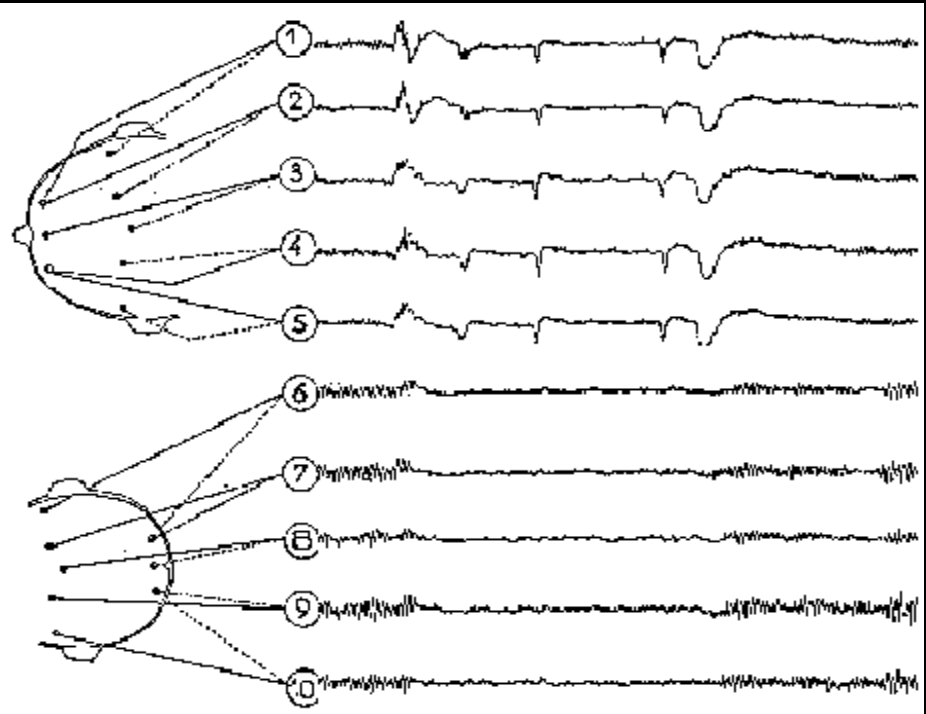
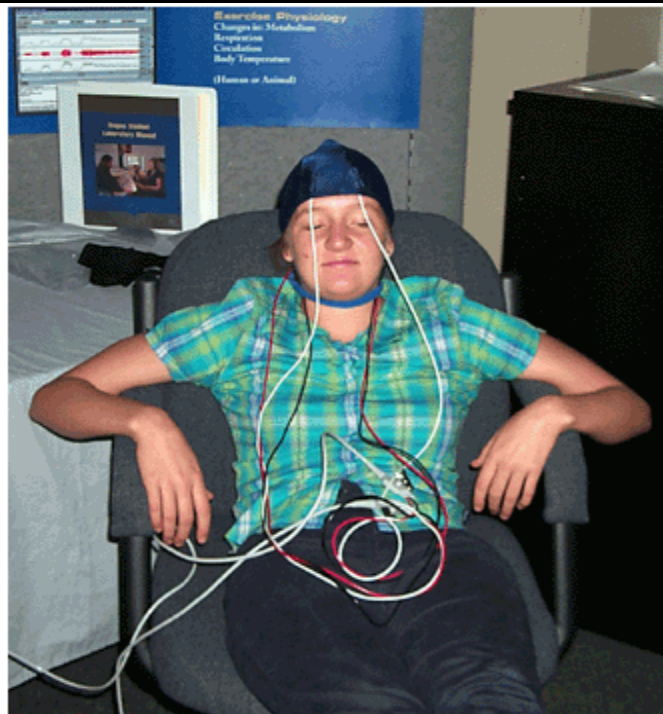**EEG**



# Magnetoencephalography (MEG)

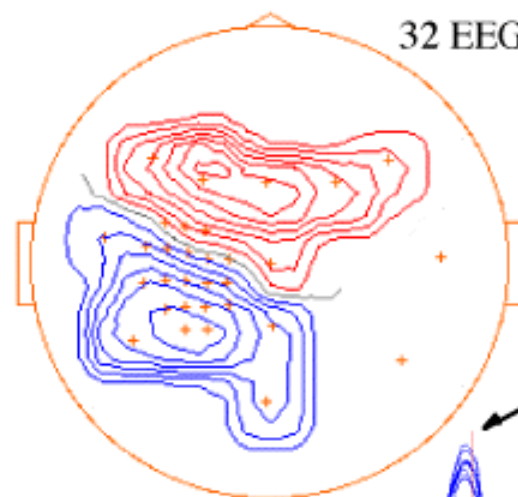
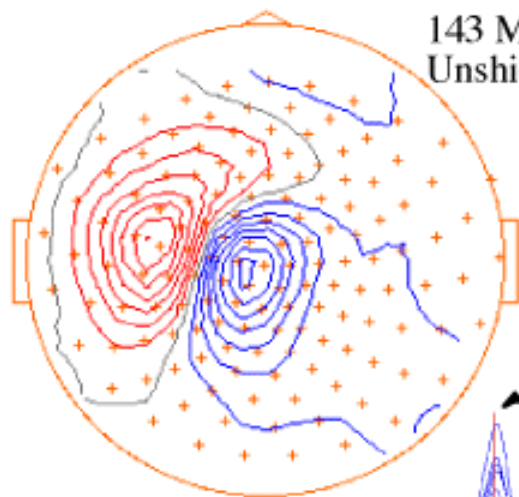


SQUID:  
Superconducting Quantum  
Interference Device



143 MEG Channels  
Unshielded Environment

32 EEG Channels

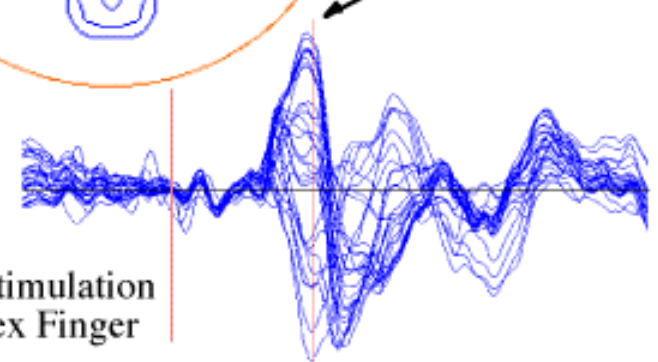
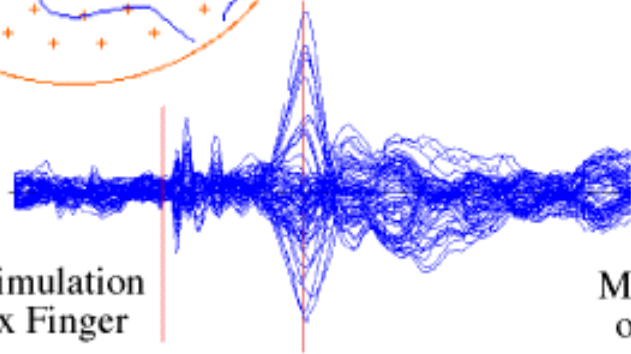


P50

P50

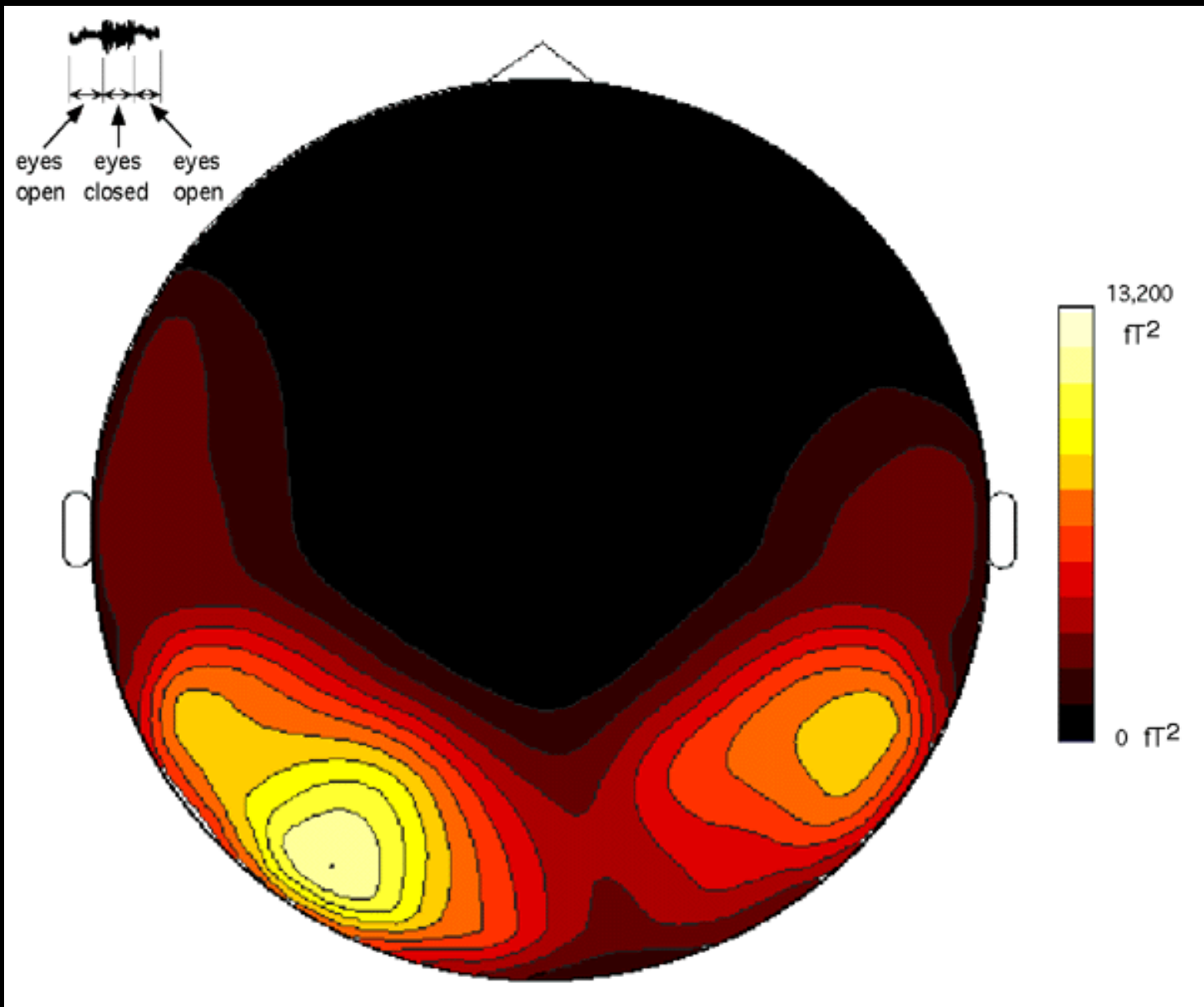
Mechanical Stimulation  
of Right Index Finger

Mechanical Stimulation  
of Right Index Finger



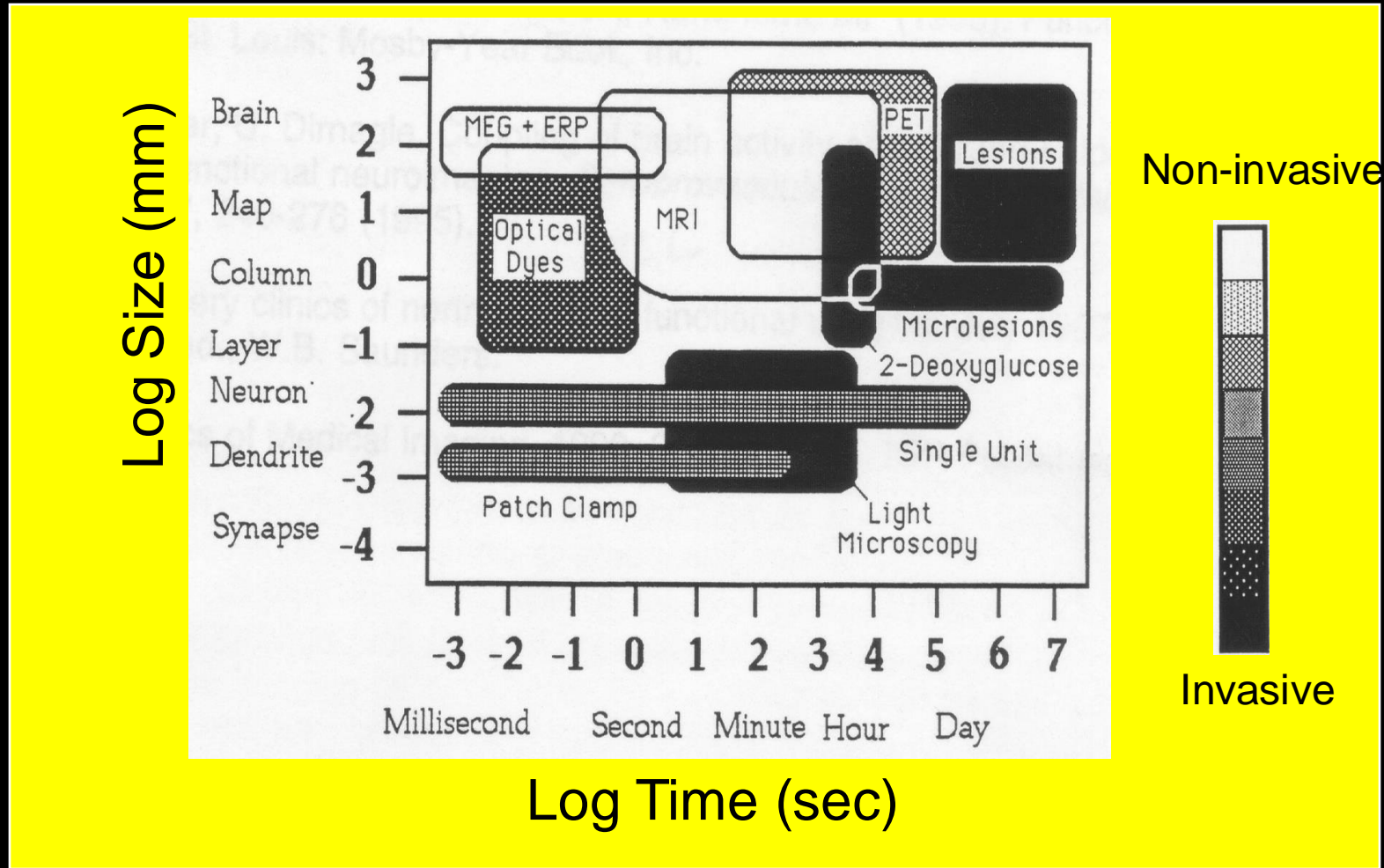


# Alpha Wave Activity Mapped with MEG

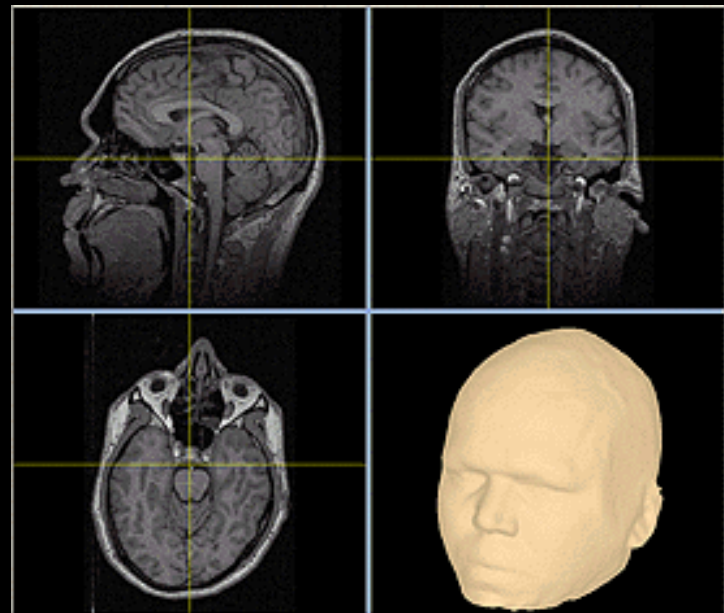
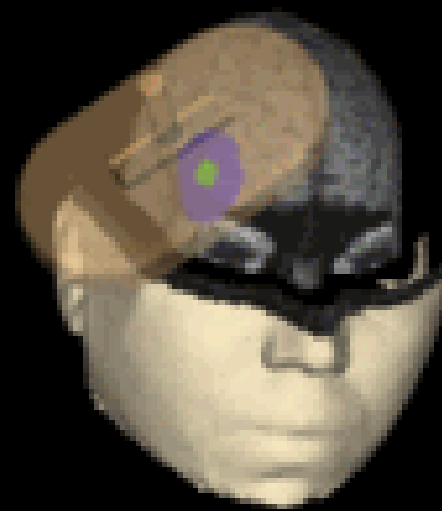
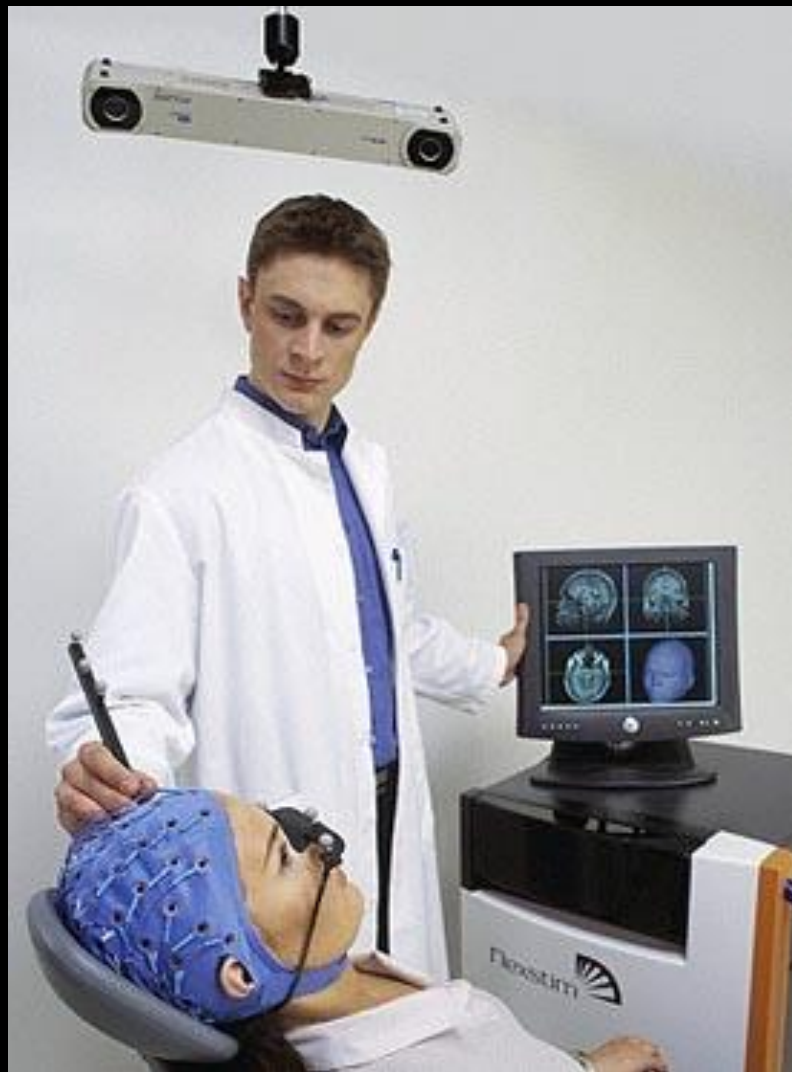


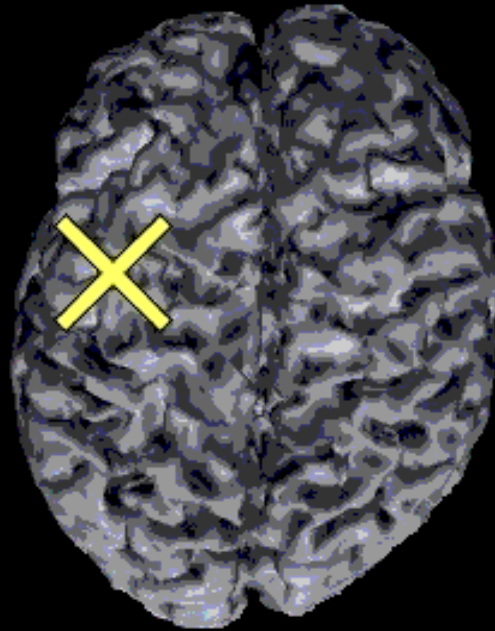
# Functional Neuroimaging Techniques



# Transcranial Magnetic Stimulation



# Transcranial Magnetic Stimulation (TMS)



# Acknowledgements

Ted Deyoe, **Medical College of Wisconsin**

Kathleen Schmainda, **Medical College of Wisconsin**

Steven Rao, **Medical College of Wisconsin**

Robert Savoy, **Massachusetts General Hospital**

Roger Tootell, **Massachusetts General Hospital**

Bradley Bookbinder, **Massachusetts General Hospital**

Randy Buckner, **Washington University, St. Louis**

Robert Innis, **National Institute of Mental Health**

Richard Coppola, **National Institute of Mental Health**

Susumu Mori, **Johns Hopkins University**

Robert Cox, **National Institute of Mental Health**

Ziad Saad, **National Institute of Mental Health**

Eric Wong, **University of California, San Diego**

Ravi Menon, **University of Western Ontario**

Nikos Logotheddis, **Max Plank Institute, Germany**

# Section on Functional Imaging Methods & FMRI Facility

